

WORLD UNION
OF
WOUND HEALING SOCIETIES



WORLD UNION OF WOUND HEALING SOCIETIES
POSITION DOCUMENT

ADVANCES IN WOUND CARE: THE TRIANGLE OF WOUND ASSESSMENT

Looking beyond the wound edge with the
Triangle of Wound Assessment

Using the Triangle of Wound Assessment
in the management of venous leg ulcers

Using the Triangle of Wound Assessment
in the management of diabetic foot ulcers



PUBLISHER

Clare Bates

MANAGING DIRECTOR

Rob Yates



www.wuwhs.net

How to cite this document

World Union of Wound Healing Societies (WUWHS), Florence Congress, Position Document.

Advances in wound care: the Triangle of Wound Assessment
Wounds International, 2016



Supported by an educational grant from Coloplast

The views expressed in this publication are those of the authors and do not necessarily reflect those of Coloplast

Produced by

Wounds International — a division of Omnia-Med Ltd
1.01 Cargo Works, 1-2 Hatfields, London, SE1 9PG

All rights reserved ©2016. No reproduction, copy or transmission of this publication may be made without written permission.

No paragraph of this publication may be reproduced, copied or transmitted save with written permission or in accordance with the provisions of the Copyright, Designs and Patents Act 1988 or under the terms of any license permitting limited copying issued by the Copyright Licensing Agency, 90 Tottenham Court Road, London, W1P 0LP

Wound assessment is complex and requires a range of clinical skills and knowledge. It has never been more important to challenge current assessment paradigms and extend our understanding of wound assessment beyond the wound edge.

It is vital that wound assessment is comprehensive, systematic and evidence-based. It should provide baseline information against which healthcare practitioners can detail and record the current status of the wound, set realistic treatment goals and monitor progress over time using appropriate interventions.

New treatments for chronic wounds have led to improvements in wound management and in the quality of assistance provided by medical and paramedical staff, but wound monitoring methodologies have not kept pace with this progress. Therefore, the study of wound healing pathophysiology and the development of new tools for the monitoring of the healing process may represent a possible optimisation of the treatment efficacy for these lesions.

The Triangle of Wound Assessment model enables evaluation of the wound bed, wound edge and periwound skin in the context of holistic patient care. Focusing on the skin beyond the edge to include the periwound skin advances the concept of wound bed preparation (TIME) by facilitating early identification of at-risk patients ensuring that appropriate prevention and treatment strategies are implemented to improve patient outcomes.

An understanding of the factors affecting periwound skin, including maceration, excoriation and increased risk of infection, is fundamental in developing new and better interventions that not only improve clinical decision making but meet the needs of patients living with a wound.

The Triangle of Wound Assessment provides a simple and intuitive framework for the consistent inclusion of periwound skin into wound assessment. This Position Document details how the Triangle of Wound Assessment can be used to assess all wound types and exemplifies how it can be implemented in the management of venous leg ulcers and diabetic foot ulcers. Used effectively, the Triangle of Wound Assessment has the potential to enable healthcare professionals to improve patient outcomes and ensure more appropriate use of healthcare resources.

Marco Romanelli

Professor and Chairman, Department of Dermatology, University of Pisa, Italy

Authors

Marco Romanelli, Professor and Chairman, Department of Dermatology, University of Pisa, Italy

Caroline Dowsett, Nurse Consultant, Tissue Viability, East London Foundation Trust, London, UK

Dorothy Doughty, WOC Nurse Clinician, Emory University Hospital, Atlanta, GA, USA

Patricia Senet, Department of Dermatology, Unit of Dermatology and Vascular Medicine, Hôpitaux Universitaires Paris Est (AP-HP), Paris, France

Christian Münter, Specialist in General Medicine, Phlebology, Bramfelder GemeinschaftsPraxis, Hamburg, Germany

José Luis Lázaro Martínez, Profesor Titular de Universidad, Director Asistencial y Jefe Unidad Pie Diabético, Clínica Universitaria de Podología, Universidad Complutense de Madrid

Reviewers

Ms Wang Ling, Chairman of Wound Ostomy Continence Committee, China Nursing Association, Peking University People's Hospital, China

Viviane Fernandes de Carvalho, PhD, CWOCN, Cell Culture and Wound Healing Research Laboratory — Plastic Surgery Division, Faculty of Medicine, University of São Paulo

David Armstrong, DPM, MD, PhD, Professor of Surgery and Director Southern Arizona Limb Salvage Alliance (SALSA), University of Arizona College of Medicine, USA

Looking beyond the wound edge with the Triangle of Wound Assessment

Globally, the demand for healthcare resources continues to grow as the demographics of the population change, long-term conditions become more prevalent, patient expectations rise and medical technology advances. Associated with this is a projected rise in the number of people with chronic wounds. A UK model for projecting future demand indicates a year-on-year increase in resource requirements of 1%–2% for wound care services. This UK model predicts that in 2019, the annual cost of providing wound care services could rise by over £200m (at 2012/13 UK prices) when compared with 2014^[1]. The impact of a wound on the patient is significant with patients reporting pain, a reduced quality of life and social isolation^[2].

In order to promote optimal wound healing and to reduce the impact of chronic wounds on the health economy, clinicians need tools and education that facilitate accurate and comprehensive wound assessment and evidence-based wound management.

The majority (79%) of patients in Europe with chronic wounds are managed in the community^[3] and it is usual for their first assessment to be undertaken by a generalist practitioner, such as a community nurse. This assessment needs to be reliable and accurate to ensure the correct treatment pathway and early referral to a specialist service where appropriate. Assessing a patient with a wound requires a range of clinical skills and knowledge to ensure an accurate diagnosis and an appropriate plan of care. The process should include a holistic patient assessment, as well as an assessment of the wound to determine the underlying cause, identify underlying conditions that may delay healing, and to determine appropriate topical therapy based on the status of the wound bed, wound edge and periwound skin.

There are many wound assessment tools currently available; however, evidence suggests that many patients are still not receiving comprehensive and knowledgeable wound assessment, which can result in delayed or inappropriate treatment and can prolong the negative impact of the wound on the individual. Inappropriate or inaccurate assessment can lead to delayed wound healing, pain, increased risk of infection, inappropriate use of wound dressings and a reduction in quality of life for patients^[4].

A recent study of 14 wound assessment tools found that while each provided a framework to record certain parameters of wound status, none met all of the criteria for optimal wound assessment and many did not guide practice in terms of setting goals for healing, planning care and determining critical interventions^[5]. For example, in one study 30% of the wounds had no diagnosis, i.e. the aetiological factors had not been determined^[6].

Furthermore, there is currently no easy-to-use validated assessment tool that integrates fully the assessment of the periwound skin together with that of the wound bed and wound edge. Assessment of the periwound skin as part of a full wound assessment is seen as integral by both healthcare professionals and patients^[7].

PRIORITIES IN WOUND ASSESSMENT AND WOUND MANAGEMENT

Optimal wound management requires attention to three critical elements:

- Determining aetiological factors, followed by interventions to correct or ameliorate those factors
- Assessing systemic factors affecting wound repair, with measures to optimise the repair process
- Assessing the wound including wound edge and periwound skin status, as a basis for topical therapies to promote healing^[8].

Caroline Dowsett,
Nurse Consultant, Tissue Viability, East London Foundation Trust, London, UK and

Dorothy Doughty,
WOC Nurse Clinician, Emory University Hospital, Atlanta, GA, USA

“The Triangle of Wound Assessment is a new framework that integrates evaluation of the periwound skin within wound assessment”

Identification and correction of aetiologic factors

An essential ‘first step’ in wound management is to determine (and correct, if possible) causative factors. Failure to identify accurately and correct causative factors results in failure to heal due to a persistent ‘cycle of injury’. Thus a patient with a pressure ulcer must be placed on an appropriate pressure redistribution surface and a turning schedule^[9]; a patient with a neuropathic ulcer requires an offloading device such as a total contact cast or removable cast walker^[10,11] and a patient with a venous ulcer needs compression and elevation^[12]. If aetiologic factors cannot be corrected, such as an arterial ulcer in a patient who is not a candidate for revascularisation, the goals of wound management must be altered to focus on stabilisation and symptom management rather than healing. Major clues as to aetiologic factors include location, wound contours and depth, and patient history (Table 1).

Systemic factors affecting healing

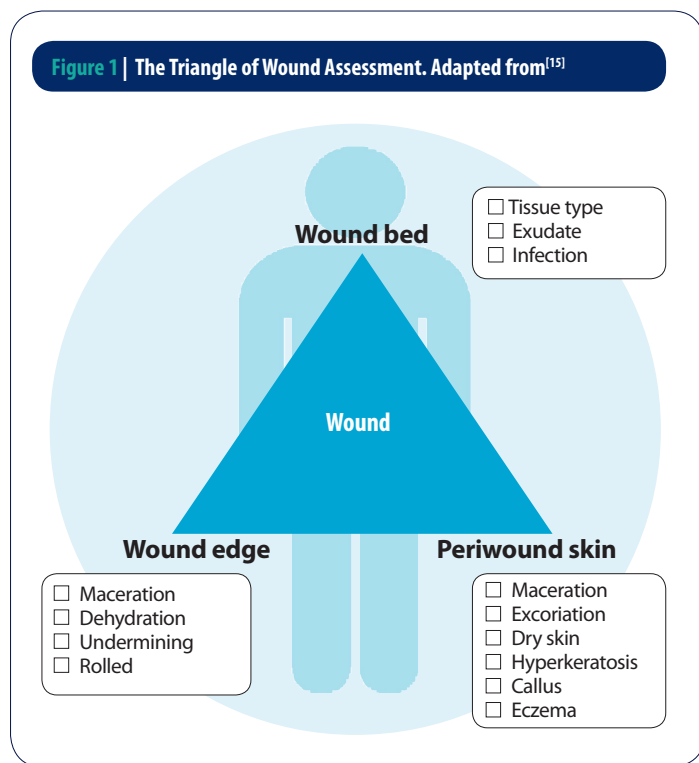
Wound healing is a systemic phenomenon that requires adequate perfusion and oxygenation, sufficient protein stores and energy intake to support anabolism, acceptable glycaemic levels, overall host competence and absence of cytotoxic therapies^[13]. This means that comprehensive wound management must include careful assessment of the individual’s overall health and factors that can impair healing, with attention to optimising the patient’s overall condition and eliminating impediments to repair^[14].

Table 1: Clues to wound aetiology			
Wound aetiology	Typical location	Characteristics	Patient history
Pressure	<ul style="list-style-type: none"> - Bony prominence - Underneath medical device 	<ul style="list-style-type: none"> - Usually round/oval (may be irregular if shear force involved) - Full thickness ulcer or purple discolouration intact skin indicating ischaemic damage - Tunnelling/undermining common - Slough/eschar common 	Immobility and inactivity May have history of sliding down in bed
Venous	<ul style="list-style-type: none"> - Lower leg, typically around malleolus 	<ul style="list-style-type: none"> - Shallow ulcer with red or red/yellow wound base - Exudative - Foot warm with good pulses and normal ABI (if no coexisting arterial disease) - Periwound skin: oedema, haemosiderosis, venous dermatitis common - May be painful; pain typically relieved by elevation 	History of lower extremity venous disease (LEVD), or signs/symptoms of LEVD (e.g. varicose veins, lower extremity oedema)
Arterial	<ul style="list-style-type: none"> - Toes/distal foot - Non-healing lesions, initially caused by trauma to lower leg or foot 	<ul style="list-style-type: none"> - Ulcers usually round, full-thickness, with pale or necrotic wound bed - Minimal exudate - Invasive infection common but signs subtle - Pain typically a major patient concern (usually partially relieved by rest and dependency) 	History of peripheral arterial disease (lower extremity arterial disease); may have history of coronary artery disease, tobacco use, hypertension, hyperlipidaemia
Neuropathic	<ul style="list-style-type: none"> - Plantar surface of foot (over metatarsal heads) - Areas of foot in contact with shoe 	<ul style="list-style-type: none"> - Ulcers usually round, full-thickness with red wound base (if no coexisting arterial disease) - Usually exudative - May or may not be painful - Periwound skin: callus common (ulcer may be located beneath callus) 	History of diabetes mellitus, Vitamin B12 deficiency, or other metabolic disease

ASSESSMENT OF WOUND STATUS: THE TRIANGLE OF WOUND ASSESSMENT

The Triangle of Wound Assessment is a new, intuitive wound assessment framework that integrates evaluation of periwound skin within wound assessment. It has been developed to facilitate an accurate and timely wound assessment in a simple and easy-to-use format that can be incorporated into any patient record system.

It uses simple descriptors and images to aid the decision-making process and facilitate continuity of care. The concept was developed from a global anthropological study conducted in 2013–2014 with the aim of gaining a better understanding of the impact of a wound on the patient.



In total, 200 wound care patients and healthcare professionals from the UK, Germany, Brazil and China were included in the study^[7]. The study sought to observe the physical, social and cultural behaviours of patients with a wound and how it affected their daily life. It also explored everyday wound management practice. The results and conclusions from the study offer a new perspective on wound healing and were validated by a quantitative survey of 412 healthcare professionals and 104 patients.

A key finding from the study showed that professionals separated wounds into three distinct, yet interconnected zones: wound bed, wound edge and periwound skin.

The wound bed, wound edge and periwound skin can be seen as three zones of a triangle, each with significant importance in wound healing (Figure 1)^[15]. The wound bed is where practitioners seek to remove devitalised tissue, manage exudate, prevent infection and reduce inflammation and promote granulation tissue formation. At the edge of the wound, the aim is to reduce the barriers to healing by eliminating dead space, debriding thickened wound edges and improving exudate management.

For the periwound skin the aim is to protect the skin

surrounding the wound from maceration, excoriation, dry skin, hyperkeratosis, callus and eczema. From this study the concept of the Triangle of Wound Assessment was developed and has been incorporated into an assessment tool for use in practice (Figure 1).

This new approach extends our understanding of wound assessment “beyond the wound edge” and expands on the current model of wound bed preparation^[14], which focuses primarily on tissue type, infection/inflammation, moisture balance and the wound edge (TIME)^[14]. The model recognises that periwound skin problems are common and may influence wound healing considerably. Correct assessment and early diagnosis of problems at the wound bed, wound edge and the periwound skin are likely to lead to interventions that improve patient outcomes and reduce healing times. They are also likely to improve levels of engagement in patients who, despite having serious underlying conditions are often primarily concerned with their wound because of the impact it has on daily life. Patients are regularly frustrated by a lack of progress in wound healing and often look for ways to act on their condition. In some cases this involves inappropriate/misuse of ointments on the periwound skin which they deem less risky than the wound bed^[7].

While the Triangle of Wound Assessment is focused primarily on assessment of the wound bed, wound edge and periwound skin, its use is predicated on the assumption that the clinician has first determined and addressed aetiological and systemic factors affecting wound repair. The Triangle of Wound Assessment should be used within the context of a holistic patient assessment, recognising the significant and individual impact that a wound has on the patient. This approach takes the clinician from the assessment process through to determining a suitable management plan focusing on the wound bed, the wound edge and the periwound skin, with the aim of facilitating healing or relieving symptoms associated with the wound. Assessment should include wound location, duration, underlying cause and wound measurements of length, width and depth at baseline and subsequent visits.

WOUND BED

Assessment of the wound bed includes observing and recording the tissue type, levels of exudate and the presence or absence of local and/or systemic wound infection (Figure 2)^[15].

“The Triangle of Wound Assessment should be used within the context of a holistic patient assessment, recognising the significant and individual impact that a wound has on the patient”

The presence of slough or necrotic tissue in a wound has long been recognised as a barrier to assessment of the wound bed, as well as a barrier to wound healing. It also acts as a potential source of wound infection and therefore its removal has many benefits. Debridement has the benefit of removing non-vascularised tissue, bacteria and cells that impede the healing process, thus providing an environment that stimulates the development of healthy tissue^[16]. The percentage reduction of necrotic and sloughy tissue provides information regarding the effectiveness of the debridement method selected and the progress in wound healing.





The Triangle of Wound Assessment provides four options in categorising the tissue in the wound bed: necrotic, sloughy, granulating and epithelialising.

It should be noted that some wounds fail to progress to granulation despite removal of necrotic and sloughy tissue: these wounds typically present with a wound bed that is pink or red but not granulating^[17]. It is critical to distinguish between a wound bed that is ‘viable but not granulating’ and a wound that is actively granulating, since the non-granulating wound may require active intervention to promote healing (e.g. attention to perfusion, bacterial loads and nutritional status).

In the event that a wound has been debrided of necrotic and sloughy tissue, but is not yet granulating, the clinician should enter ‘0%’ in each of the categories provided, and should make a note that the wound bed is viable but not granulating. This should prompt further investigation as to the reasons for failure to granulate (and appropriate interventions).

Excess exudate can delay or prevent wound healing, negatively impacting the patient and increasing the frequency of dressing change, which places great demands on resources. Exudate from chronic wounds has been shown to contain elevated levels of matrix metalloproteinases (MMPs) that prolong the inflammatory stage of wound healing and cause breakdown of the extracellular matrix^[18]. In contrast, too little exudate can lead to an overly dry wound surface, which inhibits cellular activity and wound healing. It can also lead to eschar formation, which further inhibits repair^[19].

Figure 2 | Using the Triangle of Wound Assessment — wound bed

Record wound size: length <input type="text"/> cm width <input type="text"/> cm depth <input type="text"/> cm		Record wound location	
Tissue type Please tick <input type="checkbox"/>		Exudate Please tick all <input type="checkbox"/> that apply	
Infection Please tick all <input type="checkbox"/> that apply		Local <input type="checkbox"/> Spreading/systemic <input type="checkbox"/>	
Necrotic  <input type="checkbox"/> ___%	Dry <input type="checkbox"/>	Thin/watery <input type="checkbox"/>	<input type="checkbox"/> ↑ Pain or new onset
Sloughy  <input type="checkbox"/> ___%	Low <input type="checkbox"/>	Thick <input type="checkbox"/>	<input type="checkbox"/> Erythema
Granulating  <input type="checkbox"/> ___%	Medium <input type="checkbox"/>	Cloudy <input type="checkbox"/>	<input type="checkbox"/> Oedema
Epithelialising  <input type="checkbox"/> ___%	High <input type="checkbox"/>	Purulent (yellow/brown/green) <input type="checkbox"/>	<input type="checkbox"/> Local warmth
		Pink/red <input type="checkbox"/>	<input type="checkbox"/> ↑ Exudate
			<input type="checkbox"/> Delayed healing
			<input type="checkbox"/> Bleeding/friable granulation tissue
			<input type="checkbox"/> Malodour
			<input type="checkbox"/> Pockets
Record tissue types and % of tissue visible in the wound bed		Record level and type (e.g. consistency and colour)	
Aim to remove non-viable tissue (e.g. reduce infection risk) Protect and promote new tissue growth		Aim to treat cause (e.g. compression therapy) and manage moisture balance (exception: dry gangrene)	
		Record signs and symptoms. These may be aetiology specific	
		Aim to identify infection Manage bioburden to treat infection/control odour	

The volume and the type of exudate should be assessed and recorded as this can provide useful information regarding both wound aetiology and presence or absence of infection. Thick, cloudy or purulent exudate may indicate infection as highlighted in the Triangle of Wound Assessment model. The exudate management capabilities of the dressing should be included in the assessment, as inappropriate selection can delay wound healing and increase frequency of dressing change.

Chronic wounds are often heavily colonised with bacteria, due to many factors such as prolonged duration, poor blood supply and underlying disease processes. Chronicity or stalled wound healing may be due to persistent inflammation and/or infection. The presence of biofilms may contribute to persistent inflammation and systemic debilitation, unless adequately disrupted and treated^[20]. The signs and symptoms of infection may be subtle or non-specific and can vary by wound type. The microbial bioburden in a wound can range from contamination or colonisation to critical colonisation, and local and systemic infection if not controlled appropriately^[21]. The Triangle of Wound Assessment model alerts the clinician to symptoms associated with local and spreading infection to ensure an accurate and timely assessment, and appropriate intervention.


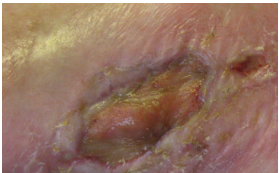



WOUND EDGE

Assessment of the wound edge can provide valuable information on wound progression and the effectiveness of the current management plan. It is a concept that is often poorly understood and applied in practice. Epithelial edge advancement is a good indication of healing and is seen as a reliable predictive indicator of wound healing.

Observations of the wound edge can provide us with valuable insights about potential problems that need to be addressed. Common problems include maceration (the mechanisms of which are described in detail in the next section), dehydration, undermining and rolled edges (Figure 3)^[15]. Dehydrated skin at the wound edge can delay healing; without moisture, cellular development and migration needed for new tissue growth are impaired. In addition, it can reduce blood flow starving the wound bed of the white blood cells needed to protect against infection. Similarly, rolled edges, which can present in wounds with inflammatory origin (e.g. *pyoderma gangensum*), can result in poor healing outcomes if not addressed appropriately. Where undermining is present, the Triangle of Wound Assessment encourages the clinician to record the degree and location of undermining using a probe and clock to illustrate position (Figure 3). Some wounds may have more than one type of wound edge problem requiring a range of interventions.

Recognising early wound size reduction by measuring advancement of the wound edge, the so-called ‘wound edge effect’, has been shown to be a useful general measure of wound healing

Figure 3 | Using the Triangle of Wound Assessment — wound edge

Maceration	Dehydration	Undermining	Rolled edges
Please tick all <input type="checkbox"/> that apply			
			
<input type="checkbox"/>	<input type="checkbox"/>	<input type="checkbox"/>  extent ____ cm	<input type="checkbox"/>
Assess edge of the wound for moisture level	Assess edge of the wound for moisture level	Use clock positions to record position Record extent of undermining	Assess amount of rolling (may be associated with thickening)
Aim to establish cause and correct Address patient concerns Refer to specialist	Aim to establish cause and correct (e.g. rehydrate) Refer to specialist	Aim to reduce the amount of undermining/ allow the edge to reattach (e.g. stimulate granulation). Refer to specialist	Aim to return the wound edge to a condition that will permit epithelial advancement Refer to specialist

outcomes in different wound types. Philips et al^[22] found that in 77% of patients with venous leg ulcers, healing outcomes could be predicted based on a wound size reduction of more than 44% at three weeks. It is therefore important to measure the wound at baseline and at frequent intervals to map progress over time (as shown in Figure 2).

PERIWOUND SKIN

Damaged or unhealthy periwound skin is a significant problem in chronic wounds^[23]; it needs to be explored and its relevance to wound progression considered within wound healing practice. The periwound area has been defined previously as the area of skin extending to 4cm beyond the wound edge^[24] but may include any skin under the dressing or even further in certain cases^[15]. It is important to demarcate this area from the existing wound and reduce the likelihood of skin breakdown by protecting it from exudate, avoiding damage to the periwound skin or preventing further damage^[14].

Periwound skin damage can result in protracted healing times, and can lead to pain and discomfort for the patient, adversely impacting their quality of life^[25]. One study found that 70% of patients had periwound skin that could be characterised as dry, macerated, excoriated or inflamed^[26]. The most common problems seen in clinical practice are associated with exudate and the term 'periwound moisture-associated skin damage' is used to describe erythema and inflammation of the skin within 4cm of the wound edge^[24,27].

Factors that increase the risk of periwound skin damage include:

- The amount of exudate and presence of heparin-binding proteins
- Bacteria and associated toxins
- Histamine produced by specific bacteria
- Proteolytic enzymes, such as matrix metalloproteinases (MMPs)
- Inflammatory cytokines (interleukin-1) in the wound exudate^[28].

When periwound skin is first exposed to exudate, the *stratum corneum* absorbs the fluid and swells. The increased moisture saturates the lower layers of the epidermis and increases the risk of maceration. This reduction in skin barrier function results in increased transepidermal water loss, leading to dryness of the skin due to a decrease in surface lipids. The patient is subsequently at increased risk of contact dermatitis.

Exudate aids the healing process of acute wounds, but in chronic wounds increased levels of protease can inhibit healing by damaging the wound bed, wound edge and periwound skin^[19]. Overhydrated skin can be slow to heal and has increased risk of infection, friction and skin damage, all of which can lead to wound enlargement^[29]. Exudate impacts the pH of the periwound skin and when it is poorly managed the subsequent change in acid mantle alters the bacterial balance/flora of the skin, reducing the balance needed for optimal healing.

While assessment of exudate (Figure 2) can offer valuable insight into the potential for periwound skin damage, it does not provide the full details necessary to inform management. Assessment in the first instance should aim to identify those patients at increased risk of periwound damage to ensure preventative measures are put in place to reduce the risk of damage^[25]. As with wound bed and wound edge, accurate assessment of the periwound skin is essential for effective wound management and treatment. The Triangle of Wound Assessment tool provides useful images to facilitate differentiation of maceration, excoriation, dry skin, hyperkeratosis, callus and eczema as each issue will require a specific treatment plan (Figure 4, page 10)^[15].

Maceration and excoriation are often used interchangeably when describing periwound damage. Maceration is the softening and breakdown of the skin; the result of prolonged exposure to moisture and wound exudate. It can also prevent cell migration across the surface of the wound and cause pain and discomfort for the patient. Excoriation on the other hand is an injury to the surface of the body caused by trauma, e.g. scratching, abrasion or chemical/thermal burn. Trauma can also be caused by repeated application and removal of adhesive tapes and dressings.

Figure 4 | Using the Triangle of Wound Assessment — periwound skin

Maceration	Excoriation	Dry skin	Hyperkeratosis	Callus	Eczema
Please tick all <input type="checkbox"/> that apply					
<input type="checkbox"/> _ _ _ cm	<input type="checkbox"/> _ _ _ cm	<input type="checkbox"/> _ _ _ cm	<input type="checkbox"/> _ _ _ cm	<input type="checkbox"/> _ _ _ cm	<input type="checkbox"/> _ _ _ cm
Assess periwound skin and record extent of any problems, e.g. 1–4cm of the wound edge					
Aim to protect periwound area and maintain intact healthy skin Establish cause and correct, e.g. minimise contact with moisture or rehydrate periwound skin			Aim to remove hyperkeratotic skin plaques and rehydrate	Aim to remove callus and offload to prevent recurrence	Aim to relieve symptoms and avoid allergens

Other wounds have dehydrated skin caused by dryness and/or hyperkeratosis. Patients with venous leg ulcers often have lipodermatosclerosis, hyperpigmentation and dry skin in the periwound area, including callus and eczema.

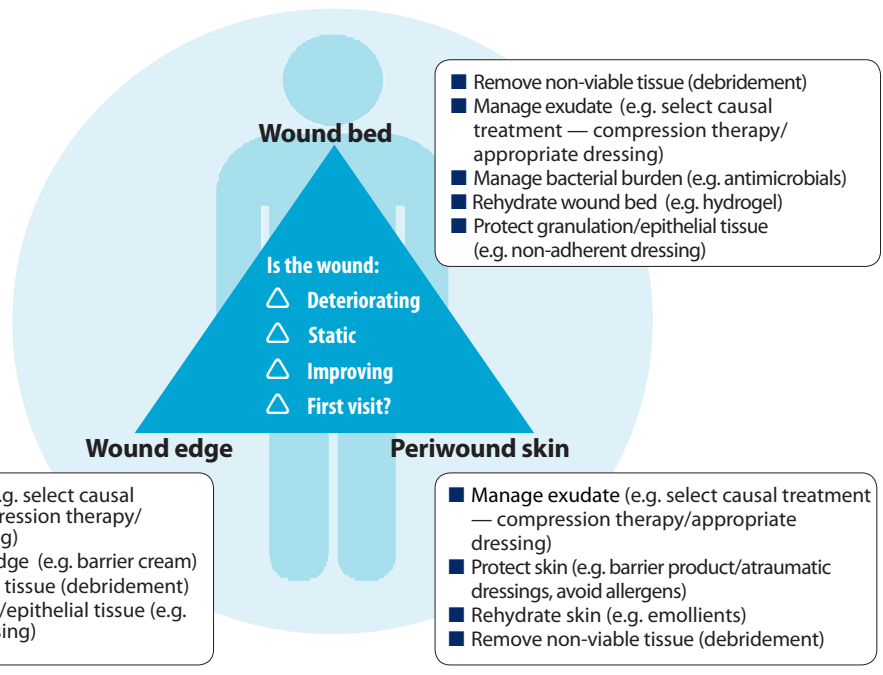
DEVISING A MANAGEMENT PLAN

Using the Triangle of Wound Assessment encourages the clinician to identify barriers to wound healing at the wound bed, wound edge and periwound skin, and to develop a plan of care (Figure 5) to address these problems, which may include removal of non-viable tissue, management of excess exudate, protection of granulation tissue and skin protection and rehydration. Patients should be included in setting treatment goals — it helps to ensure that their concerns are addressed and they feel more in control.

Figure 5 | Using the Triangle of Wound Assessment — devising a management plan

Accurate and timely wound assessment is important to ensure correct diagnosis and for developing a plan of care to address patient, wound and skin problems that impact healing.

Identify treatment goal, e.g. 100% granulation tissue/ healed wound. **If no signs of improvement after 2–4 weeks, review treatment plan/refer to specialist**



CONCLUSION

The development of an intuitive wound assessment tool that goes beyond the wound edge to include the periwound skin extends the opportunity for improved decision-making. It further advances the concept of wound bed preparation (TIME) by facilitating early identification of patients at risk of, or with periwound skin problems. The Triangle of Wound Assessment can be used to assess all wound types including pressure ulcers, leg ulcers, diabetic foot wounds and any other chronic wounds. Used effectively it offers the opportunity to improve patient outcomes and ensure more appropriate use of healthcare resources. It provides a simple framework for the consistent inclusion of periwound skin into wound assessment.

REFERENCES

- Dowsett C, Bielby A, Searle R. Reconciling increasing wound care demands with available resources. *Journal of Wound Care* 2014 Nov; 23(11): 552-62.
- Price P. Psychological impact of skin breakdown. In: Flanagan M (ed) *Wound Healing and Skin Integrity Principles and Practice*. Oxford: John Wiley & Sons, 2013; 102-13.
- Posnett J, Gottrup F, Lundgren H, Saal G. The resource impact of wounds on healthcare providers in Europe. *Journal of Wound Care* 2009; 18(4): 154-161.
- Ousey K, Cook L. Understanding the importance of holistic wound assessment. *Pract Nurse* 2011; 22(6): 308-14.
- Greatrex-White S, Moxey H. Wound assessment tools and nurse's needs: an evaluation study. *International Wound Journal* 2013; 12(3): 293-301 doi:10.1111/iwj
- Guest JF, Ayoub N, McLwraith T et al. Health economics burden that wounds impose on the National Health Service in the UK. *BMJ Open* 2015; 5:e009283. doi:10.1136/bmjopen
- Dowsett C, Gronemann M, Harding KG. Taking wound assessment beyond the edge. *Wounds International* 2015; 6(1): 19-23. Available at: http://www.woundsinternational.com/media/other-resources/_/1189/files/twa-made-easy_web.pdf [accessed 23.02.16].
- Krapfl L, Pierce B. General principles of wound management. In: Doughty D and McNichol L (eds) *WOCN Core Curriculum: Wound Management*. Philadelphia, USA. Lippincott Williams & Wilkins 2015.
- Thomas DR. Prevention and treatment of pressure ulcers. *Journal of the American Medical Directors Association* 2006 Jan 31; 7(1): 46-59.
- Kerr, M (2012) *Inpatient Care for People with Diabetes – The Economic Case for Change*. NHS Diabetes. Available at: <http://bit.ly/1LHdese> (accessed 04.04.2016)
- Fife CE; Carter MJ, Walker D (2010) Why is it so hard to do the right thing in wound care? *Wound Rep Reg* 18: 154-8
- Fletcher J, Moffatt C, Partsch H, Vowden K, Vowden P. *Principles of Compression in Venous Disease. A Practitioner's Guide to Treatment And Prevention of Venous Leg Ulcers*. Wounds International 2013, London. Available at: <http://bit.ly/13pi090> (accessed 04.04. 2016).
- Broughton 2nd G, Janis JE, Attinger CE. The basic science of wound healing. *Plastic and Reconstructive Surgery* 2006 Jun; 117(7 Suppl): 12S-34S.
- Schultz GS, Barillo DJ, Mozingo DW, Chin GA. Wound bed preparation and a brief history of TIME. *International Wound Journal* 2004 Apr 1; 1(1): 19-32.
- Dowsett C, Protz K, Drouard M, Harding KG. Triangle of Wound Assessment Made Easy. *Wounds International* May 2015. Available at: <http://www.woundsinternational.com/made-easys/view/triangle-wound-assessment> [accessed 23.02.16]
- Schultz GS, Sibbald RG, Falanga V et al. Wound Bed Preparation; a systematic approach to wound management. *Wound Repair Regen* 2003; 11(2): 1-28.
- Bates-Jensen B. Assessment of the patient with a wound. In: Doughty D and McNichol L (eds) *WOCN Core Curriculum: Wound Management*. Philadelphia, USA. Lippincott Williams & Wilkins 2015.
- Tengrove NJ, Stacey MC, MacAuley S et al. Analysis of the acute and chronic wound environments: the role of proteases and their inhibitors. *Wound Repair Regen* 1999; 7(6): 442-52.
- Romanelli M, Vowden K, Weir D. Exudate management Made Easy. *Wounds International* 2010; 1(2). Available at www.woundsinternational.com
- Wolcott RD, Dowd S, Kennedy J, Jones CE. Biofilm-based wound care. In: Sen C (ed). *Advances in Wound Care* 2010; 311-17.
- World Union of Wound Healing Societies. *Principles of Best Practice: Wound Infection in Clinical Practice. An International Consensus*. Wounds International 2008
- Phillips TJ, Machado F, Trout R et al. Prognostic indicators in venous ulcers. *Journal of the American Academy of Dermatology* 2000 Oct; 43(4): 627-30.
- Cartier H, Barrett S, Campbell K, et al. Wound management with the Biatain Silicone foam dressing: A multicentre product evaluation. *Wounds International* 2014; 10(4): 26-30.
- Dowsett C, Allen L. *Moisture associated skin damage Made Easy*. Wounds UK 2013. Available at www.wounds-uk.com/pdf/content_10961.pdf [accessed 16.02.2016].
- Lawton S, Langoen A (2009). Assessing and managing vulnerable periwound skin. *World Wide Wounds* 2009. Available from: <http://www.worldwidewounds.com/2009/October/Lawton-Langoen/vulnerableskin-2.html>
- Ousey K, Stephenson J, Barrett S et al. Wound care in five English NHS Trusts. Results of a survey. *Wounds UK* 2013; 9(4): 20-8.
- White R and Cutting K. Interventions to avoid maceration of the skin and wound bed. *Br J Nurs* 2003; 12,20; 1186-1201
- Gray M, Weir D. Prevention and treatment of moisture-associated skin damage (maceration) in the periwound skin. *J Wound Ostomy Continence Nurse*. 2007, 34:153-157.
- Colwell JC, Ratliff CR, Goldberg M, Baharestani MM, Bliss DZ, Gray M, Kennedy-Evans KL, Logan S, Black JM. MASD part 3: peristomal moisture-associated dermatitis and periwound moisture-associated dermatitis: a consensus. *Journal of Wound Ostomy & Continence Nursing* 2011 Sep 1; 38(5): 541-53.

Using the Triangle of Wound Assessment in the management of VLUs

Venous leg ulcers (VLUs) pose significant challenges to patients and healthcare systems; they are costly to the patient and to the health economy. About 1% of the western population will suffer from a VLU during their lifetime^[1]. Patients report that having a VLU has a negative impact on all aspects of daily living and may cause depression, anxiety, pain and restricted mobility^[2].

Prevalence of VLUs increases with age, and as the elderly population continues to grow, the challenge of managing patients with VLUs will continue. Despite guidelines on best practice, average healing rates for patients with VLUs remain between 45% and 70% at six months with many patients not receiving the gold standard treatment of compression^[3].

Appropriate wound assessment can help in the treatment and management of VLUs. Wound assessment should be comprehensive, systematic and evidence-based giving healthcare practitioners information against which they can establish the current status of the wound, set realistic treatment milestones and monitor progress of appropriate interventions. Optimising wound management means focusing on assessment and treatment beyond the wound edge to include the periwound skin. Thorough and accurate assessment of a wound is critical to improving patient outcomes and improving quality of life.

As a framework the Triangle of Wound Assessment extends the current concepts of wound bed preparation and TIME beyond the wound edge to provide a guide to optimising wound management. The division of the wound into three zones^[4] — wound bed, wound edge and periwound skin — enables clinicians to assess thoroughly and accurately a VLU within the context of holistic patient assessment and treatment of the underlying venous insufficiency with compression therapy.

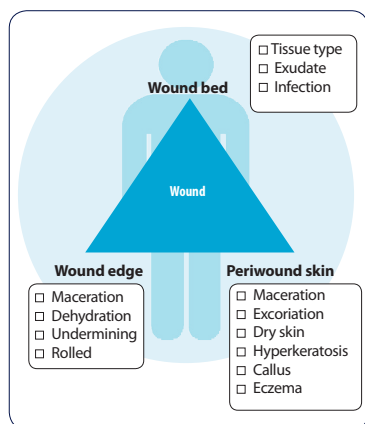
The aim is to gain an overview of the patient's medical condition; the cause, duration and status of the wound, along with other factors that may slow or prevent healing^[5,6,7] including;

- Comorbidities, e.g. diabetes, cardiovascular disease, respiratory disease, venous/arterial disease, malignancy
- Medications, e.g. corticosteroids, anticoagulants, immunosuppressants, chemotherapeutic agents, NSAIDs
- Systemic or local infection (e.g. osteomyelitis)
- Reduced oxygenation and tissue perfusion
- Increased age
- Pain
- Poor nutrition and hydration
- Lifestyle factors, e.g. high alcohol intake, smoking, obesity.

Recent Best Practice Guidelines on simplifying VLU management^[3] suggest a pathway approach to assessment to determine if they are simple or complex. This approach helps to determine the prognosis and the correct interventions for improving patient outcomes^[3].

Caroline Dowsett,
Nurse Consultant,
Tissue Viability, East
London Foundation Trust,
London, UK and **Patricia
Senet**, Department of
Dermatology, Unit of
Dermatology and Vascular
Medicine Hôpitaux
Universitaires Paris Est (AP-
HP), Paris, France

Figure 1 | The Triangle of Wound Assessment. Adapted from^[4]



Physiopathology of VLU

The mechanisms that impair wound healing in VLUs are complex and include comorbidities, and local and systemic factors. The Triangle of Wound Assessment should be used within the context of holistic patient assessment and treatment of the underlying factors. Ambulatory venous hypertension leads to an increase in capillary permeability that is responsible for a chronic leakage of fibrinogen. The formation of extravascular, cross-linked fibrin around the capillaries, noted histologically as fibrin cuffs, contributes to tissue hypoxia injury^[8,9]. Several factors that are linked together, contribute to:

■ Persistent and chronic inflammation

Long-term ischaemia/reperfusion injury in venous hypertension leads to chronic inflammation related to the accumulation of leukocytes in blood vessel lumens, leukocyte extravasation, and elevated expression of tissue metalloproteinases and pro-inflammatory cytokines, mainly IL-1 β and TNF α ^[8,10]. Elevated metalloproteinases degrade the extracellular matrix and impair cell migration. Moreover, iron overloading of macrophages, found in human chronic VLUs, induces a macrophage population *in situ* with an unrestrained pro-inflammatory M1 activation state. Via enhanced TNF α and hydroxyl radical release, this macrophage population perpetuates inflammation and induces senescence in resident fibroblasts^[8,11].

■ Cellular senescence

Considerable evidence from several teams suggests that the resident dermal fibroblasts in non-healing VLUs (i.e. large area and long duration) have acquired an abnormal phenotype that is not conducive to appropriate tissue repair^[10,12,13,14]. Decreased growth in cell culture and other characteristics of cellular senescence have been observed in fibroblasts isolated from non-healing VLUs, compared with normal non-wound skin fibroblasts from the same patients^[12,13,14]. The mechanism of cellular ageing, responsible for the dysfunctional healing phenotype, is related to elevated levels of oxidative stress and is telomere independent^[10,15,16]. Moreover, keratinocytes display impaired migratory capacities that fail to restore the epidermis^[17].

■ Impaired angiogenesis

Decreased local angiogenesis is observed in VLU wound edges that may result from the persistent inflammatory and tissue-destructive response. This, in turn, leads to increased degradation of proangiogenic growth factor, such as vascular endothelial growth factor. The impairment of the recruitment of local and systemic stem cells may also play a role in delayed healing of VLUs^[16].

THE TRIANGLE OF WOUND ASSESSMENT IN VLU MANAGEMENT

The Triangle of Wound Assessment has the potential to support and improve assessment of VLUs as it can: aid differential diagnosis; establish the correct pathway for the patient i.e. simple or complex VLU pathway and identify local problems at the wound bed, wound edge and periwound skin that may negatively impact on wound healing i.e. infection or maceration.

The periwound skin must be assessed for signs of high levels of exudate, maceration and excoriation. Patients with VLUs often have lipodermatosclerosis, hyperpigmentation and dry skin in the periwound area^[18]. As a result skin becomes thin and is easily damaged.

The three distinct zones of a wound — the wound bed, wound edge and periwound skin — call for different approaches in assessment and treatment of any wound (Figure 1). The Triangle of Wound Assessment combined with best practice guidelines on VLU management has the potential to improve patient outcomes, reduce time to healing and ensure those patients with complex aetiologies are referred to the most appropriate specialist (Figure 2).

Figure 2 | Using the Triangle of Wound Assessment in assessing and treating VLU. Adapted from^[4]

VLU are the most common type of chronic lower limb wound and are the result of disease or disrupted function of the veins, known as chronic venous insufficiency.

VLU characteristics

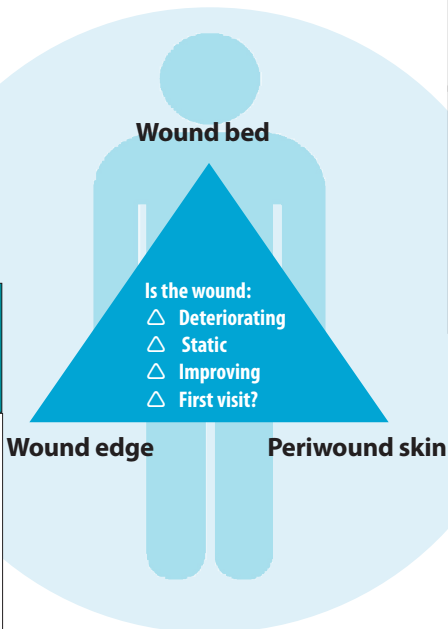
- Irregular sloping margins
- Usually shallow
- Fibrinous, granulating base
- High exudate levels
- Variable size: from small to encircling the leg
- Maybe painful

Wound edge: special considerations

- A raised wound edge can indicate malignancy
- Discolouration e.g. purplish colour, can indicate an inflammatory ulcer, such as *pyoderma gangrenosum*

Management plan

- Manage exudate (check for optimal compression therapy/appropriate dressing)
- Remove non-viable tissue (debridement)
- Protect granulation/epithelial tissue (e.g. non-adherent dressing)
- Manage bacterial burden (e.g. antimicrobials)
- Rehydrate wound edge (e.g. barrier cream)
- Consider referral if the wound edge is abnormal or there is no reduction in size in 4 weeks



Wound bed: special considerations

- Infection can present itself as new ulcer formation within inflamed edges of pre-existing ulcers

Management plan

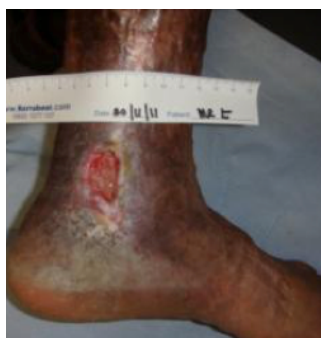- Remove non-viable tissue — autolytic debridement with the use of compression
- Manage exudate (compression therapy with appropriate dressing)
- Manage bacterial burden: cleansing and debridement. Use of antimicrobials
- Protect granulation/epithelial tissue (e.g. non-adherent dressing)

Periwound skin: special considerations

- Varicose eczema due to venous disease
- Lower limb oedema

Management plan

- Prevent periwound skin damage
- Manage oedema and exudate (compression therapy/appropriate dressing)
- Protect skin (e.g. exudate management, barrier product/atraumatic dressings, avoid allergens)
- Rehydrate dry skin (e.g. emollients) and treat eczema (e.g. topical steroids)
- Remove non-viable tissue (debridement)

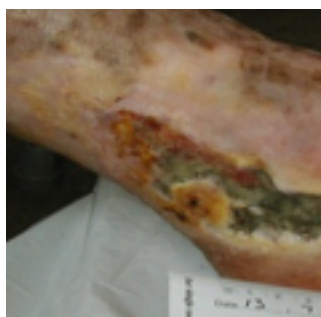

Picture 1: Uncomplicated VLU

WOUND BED MANAGEMENT

The challenge for effective wound bed management is the early identification of those ulcers that are unlikely to heal with compression therapy alone. Assessment of the tissue type, exudate levels and the presence or absence of infection will help to determine the most appropriate pathway and intervention required to optimise the wound bed. Baseline and serial measurement of the wound size (length, depth and width) and appearance help to establish a treatment pathway, and to monitor and evaluate the patient's response to the intervention^[7,19].

Tissue type: The specific characteristics of the tissue within a wound bed play a very important role in the wound-healing continuum. Accurate description of this tissue is an important feature of wound assessment. Where tissue is non-viable or deficient, wound healing is delayed; it also provides a focus for infection, prolongs the inflammatory response, mechanically obstructs contraction and impedes re-epithelialisation^[20].

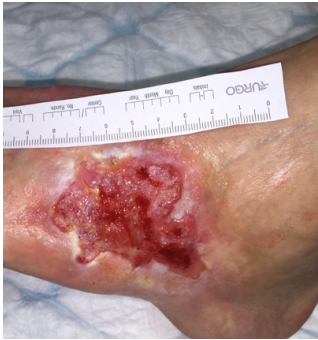

Picture 2: Complex VLU

It is important to record tissue types and the percentage of tissue visible in the wound bed. The aim is to remove non-viable tissue — and reduce the risk of infection — and protect and promote new tissue growth^[4]. Treatment choices should aim to improve the wound bed, promote healing and protect the periwound skin.

The majority of uncomplicated VLUs have relatively little sloughy or necrotic tissue at the wound bed and do not need debridement (Picture 1). Loose slough, if present, will usually auto-debride with compression therapy alone. More complex VLUs may however contain devitalised tissue, which can lead to delayed wound healing and will need debridement (Picture 2). Limited sharp debridement is often sufficient as slough is superficial and rarely is maintenance debridement indicated for VLUs^[21].

Case 1: Patient, 49 years old, presents with a leg ulcer on the dorsum of the foot that he has had for 7 years. It was treated as a VLU with daily dressings and venous compression by stockings (15 mmHg at the ankle). There has been no change in the wound size since year one



Wound bed

Tissue type: Granulation tissue. Granulating tissue of the wound bed was not friable but slightly exophytic and hardened

Exudate level: Low

Type of exudate: Thin/watery, sometimes red (bloody)

Infection: Infection

Biopsies (n=5) on the wound bed and the wound edges were performed because there was no change in the wound size despite standard care, and because of the presence of indurated granulating tissue in the wound bed, without epithelialisation. The biopsies revealed squamous cell carcinoma that required surgical excision and a cutaneous graft

Exudate: VLUs usually produce moderate to large volumes of exudate, which can delay wound healing and cause maceration of the wound edge and periwound skin. Chronic exudate leads to the breakdown of the extracellular matrix proteins and growth factors, prolongs inflammation and inhibits cell proliferation^[22]. Assessment of exudate should include the level and type of exudate, and its interaction with the dressing and compression therapy.

The removal of oedema in the leg using sustained compression is fundamental to achieving moisture balance (SIGN 2010). Leakage or strikethrough has the potential to lead to the development of infection resulting in an increased volume of exudate and a change in consistency to thick, purulent and cloudy. The Triangle of Wounds Assessment framework enables clinicians to assess the potential for complication using a simple rating system to record the level and type of exudate, e.g. consistency and odour, with the aim of treating the cause (e.g. compression therapy) and managing moisture balance. Effective exudate management includes not only ensuring correct assessment and treatment but also addressing patient concerns and quality of life^[22].

Infection: VLUs by their chronic nature contain high levels of bacteria, which will need to be controlled to facilitate healing. Infection may produce different signs and symptoms in wounds of different aetiologies^[23]. Usually infection in VLUs will present with delayed wound healing, cellulitis, increased pain and new ulcer formation within inflamed margins of pre-existing ulcers (EWMA, 2005)^[24].

Case 1 illustrates assessment of wound bed according to the Triangle of Wound Assessment framework.

Assessment should include a full evaluation of the patient and should consider immune status, comorbidities, wound aetiology and other factors that may increase the risk of infection (WUWHS, 2008)^[25]. The Triangle of Wound Assessment alerts the clinician to symptoms associated with local and spreading infection in VLUs to ensure an accurate and timely diagnosis and intervention. It enables clinicians to record signs and symptoms of infection that may be aetiology specific with the aim of identifying infection, and managing the bioburden to treat the infection and control odour.

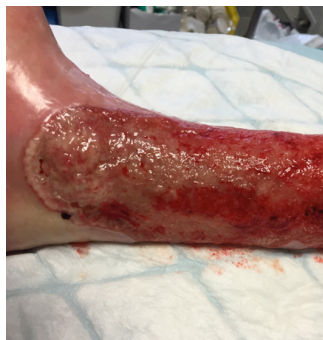WOUND EDGE MANAGEMENT

The wound edge needs to be moist, intact, attached to and flush with the base of the wound to enable migration of epithelial cells. Wound edge migration is a good predictor of healing in patients with VLUs^[26], so regular wound measurement is essential to evaluate the effectiveness of the treatment plan. Usually VLUs have shallow sloping edges that will encourage epithelialisation with the correct compression and wound bed preparation. Assessment of the wound edge should include observation for maceration, dehydration, undermining or rolled or abnormal edges.

At the wound edge the aim is to lower barriers to effective wound healing by reducing dead space, debriding thickened or rolled edges, improving exudate management, and reducing maceration through appropriate treatment and dressing selection. Assessment of the edge of the wound can provide information on wound aetiology, healing progression, and establish appropriateness and effectiveness of the current treatment plan^[4].

Maceration: The wound edge should be inspected for the presence of maceration resulting from high levels of exudate. It should be assessed for moisture levels. The aim is to establish the cause of excess moisture — e.g. use of inappropriate dressings, poor application of compression therapy or where wear times have been exceeded — and

Case 2: Patient, 80 years old, without any peripheral arterial disease or venous disease on echo-doppler examination. Sudden onset of an extremely painful leg ulcer, enlarged rapidly despite systemic antibiotics. Using the Triangle of Wound Assessment framework to assess the wound, the following was identified:



Wound bed

Tissue type: Granulating (50%) and sloughy (50%)

Exudate level: Medium

Type of exudate: Purulent

Systemic infection: No sign of local infection except friable granulation tissue. No change in pain, no oedema, no erythema. No effect of systemic antibiotics

Wound edge: Between 3 and 7 on the clock face, wound edge was undermined, infiltrated and purulent, showing a rapid progression

Biopsies supported a presumptive diagnosis of *pyoderma gangrenosum*, showing a dense neutrophilic infiltrate in the dermis. A colonoscopy was performed and revealed the inflammatory bowel disease Crohn's disease

correct it, as well as to address any concerns the patient may have. They may require specialist referral.

Dehydration: It is important to achieve and maintain moisture balance to ensure optimal healing outcomes for VLUs. The aim should be to establish the cause of dehydration and take corrective action (e.g. rehydrate). It is important to treat the underlying clinical condition causing the moisture imbalance^[27].

Undermining: The extent of the undermining (e.g. depth), identified by digital examination or use of a probe, should be recorded. In addition, the position of the undermining should be detailed using the number positions on a clock face. The aim is to reduce the undermining using appropriate treatment that enables the edge to reattach (e.g. stimulate granulation).

Rolled edges: These can present in wounds that have an inflammatory origin, e.g. *pyoderma gangrenosum*. Early diagnosis is important in such cases, as failing to provide appropriate second line therapy can result in poor healing outcomes. Clinicians should assess the amount of rolling (which may be associated with thickening) and aim to return the wound edge to a condition that supports epithelial advancement.

Case 2 illustrates assessment of wound bed and wound edge according to the Triangle of Wound Assessment framework.

PERIWOUND SKIN MANAGEMENT

Problems of the periwound skin are common in VLU patients. Damage in this area increases healing times, can cause pain and discomfort and adversely affect quality of life^[28].

In a UK study, 70% of patients had periwound skin problems that could be characterised as dry, macerated, excoriated or inflamed^[29]. Factors that increase the risk of periwound skin damage include the amount of exudate and presence of heparin-binding proteins, bacteria and associated toxins, histamine produced by specific bacteria, proteolytic enzymes, such as matrix metalloproteinases (MMPs), and inflammatory cytokines in the wound exudate^[30].

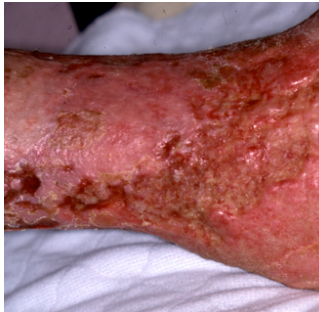The high levels of exudate alter the pH of the periwound skin and when it is poorly managed the subsequent change in acid mantle changes the bacterial balance/flora of the skin, reducing the balance needed for optimal healing.

When periwound skin is first exposed to exudate, the *stratum corneum* absorbs the fluid and swells. The increased moisture saturates the lower layers of the epidermis and increases the risk of maceration. This reduction in skin barrier function results in increased transepidermal water loss, leading to dryness of the skin due to a decrease in surface lipids. The patient is subsequently at increased risk of contact dermatitis^[31].

It is necessary to define the periwound skin from the existing wound and reduce the potential for skin breakdown due to high levels of exudate by protecting the skin and preventing further damage. Assessment of the periwound skin should include:

- Maceration — there is an increased risk due to high exudate levels
- Excoriation
- Hyperkeratosis
- Contact dermatitis — patients with VLUs show a great tendency towards allergy^[32]
- Varicose eczema due to venous disease
- Lower limb oedema.

Case 3: Patient treated for a VLU, with multilayer compression and foam dressing, twice a week



Wound bed: Granulation/epithelialisation, low exudate, no signs of infection

Wound edge: Dehydrated

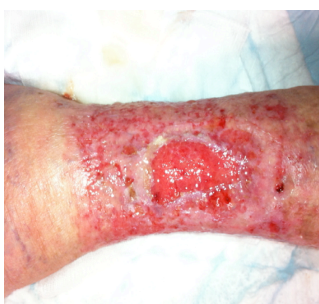Periwound skin: Dry skin, eczema

Cause: No moisture cream was applied during local wound care.

Antiseptics were used for ulcer cleansing (chlorhexidine), that may induce irritative or contact dermatitis

Treatment: Stop antiseptic, cleanse with saline. Use topical steroids followed by systematic application of an emollient before applying bandages

Case 4: Patient with a VLU treated with multilayer compression and foam dressing, twice a week. Foam dressing was stopped for an unknown reason, and a silicone wound contact layer was applied under compression. After 2 weeks there was apparition of erythematous skin plaques on the periwound skin, with pustules that formed erosions and crusts. Pustules were aseptic



Wound bed: Granulation tissue, medium-to-high levels of exudate, no evidence of infection

Wound edge: Macerated

Periwound skin: Maceration with superficial erosions, crusts, pustules

Cause: Erosive pustular dermatosis

Treatment: Topical steroids; discontinue silicone dressing

Using the Triangle of Wound Assessment enables early identification and management of the wound bed, wound edge and periwound skin problems. By identifying, measuring and recording the extent of any of these issues, e.g. <1–4cm of the wound edge, it is possible to ensure an appropriate intervention and treatment, e.g. removing hyperkeratotic skin plaques and rehydrating; removing calluses and using offloading to prevent recurrence; alleviating the symptoms of eczema and avoiding allergens in the future^[4].

Cases 3 and 4 illustrate assessment of wound bed, wound edge and periwound skin using the Triangle of Wound Assessment framework.

DEVISING A TREATMENT PLAN FOR VLUs

Using the Triangle of Wound Assessment framework enables accurate assessment of the wound bed, wound edge and periwound skin, resulting in a correct diagnosis and the development of a integrated care plan^[4] that addresses wound and skin problems in addition to the wider needs of the patient. It aids identification of problems that are delaying healing, e.g. eczema (Case 3) or maceration (Case 4), enabling clinicians to investigate the cause and move to a more appropriate treatment or intervention.

In developing a treatment plan for VLUs it is important to accurately assess the wound to ensure correct diagnosis and development of a management plan that takes into consideration the holistic needs of the patient, as well as addressing wound and skin problems that may impact healing. It is important to:

- Manage wound exudate
- Protect granulation tissue
- Treat periwound skin problems (here you would consider the use of topical steroids)
- Patch testing to identify potential allergens where contact sensitivity is suspected.

CONCLUSIONS

VLUs have a significant impact on the lives of patients and their families. The mechanisms that impair wound healing in patients with VLUs are complex making assessment and management challenging for clinicians and leg ulcer services. It recognises that the patient, and treatment of underlying aetiology, is central to the process of assessment.

The Triangle of Wound Assessment is a simple and easy-to-use framework that provide tools to improve assessment of the wound bed, wound edge and periwound skin. It can be incorporated into care pathways, education and training programmes, and treatment protocols for VLUs, as well as for other types of wounds.

The framework combined with best practice guidelines on VLU management has the potential to improve patient outcomes, reduce time to healing and ensure those patients with complex aetiologies are referred to the most appropriate specialist.

REFERENCES

1. O'Meara S, Cullum N, Nelson EA et al. Compression for venous leg ulcers: Cochrane Database Syst Rev 2012; 11:CD000265 (PubMed).
2. Green J, Jester R, McKinley R et al. The impact of chronic venous leg ulcers: a systematic review. *Journal of Wound Care* 2014; 23(12): 601-12.
3. Harding K et al. *Simplifying venous leg ulcer management. Consensus recommendations*. Wounds International 2015. Available at: <http://www.woundsinternational.com/consensus-documents/view/simplifying-venous-leg-ulcer-management> (accessed 23.02.16).
4. Dowsett C, Protz K, Drouard M, Harding KG. *Triangle of Wound Assessment Made Easy*. Wounds International 2015. Available at: <http://www.woundsinternational.com/made-easys/view/triangle-wound-assessment> (accessed 23.02.16).
5. Anderson K, Hamm RL. Factors that impair wound healing. *J Am Coll Clin Wound Specialists* 2012; 4(4): 84-91. 11.
6. Guo S, DiPietro LA. Factors affecting wound healing. *J Dent Res* 2010; 89(3): 219-29. 12.
7. Gethin G. The importance of continuous wound measuring. *Wounds UK* 2006; 2(2): 60-8.
8. Chen WYJ, Rogers AA. Recent insights into the causes of chronic leg ulceration, in venous diseases and implications on other types of chronic wounds. *Wound Rep Regen* 2007; 15(4): 434-49.
9. Phillips LJ, Sarkar R. Molecular characterisation of post-thrombotic syndrome. *J Vasc Surg* 2007; 45(6): A116-A122.
10. Wall IB, Moseley R, Baird DM et al. Fibroblast dysfunction is a key factor in the non-healing of chronic venous leg ulcers. *J Invest Dermatol* 2008; 128(10): 2526-40.
11. Sindrilaru A, Peters T, Wieschalka S et al. An unrestrained proinflammatory M1 macrophage population induced by iron impairs wound healing in humans and mice. *J Clin Invest* 2011; 121(3): 985-97.
12. Stanley AC, Park HY, Phillips TJ et al. Reduced growth of dermal fibroblasts from chronic venous ulcers can be stimulated with growth factors. *J Vasc Surg* 1997; 26(6): 994-1001.
13. Mendez MV, Stanley A, Park HY et al. Fibroblasts cultured from venous ulcers display cellular characteristics of senescence. *J Vasc Surg* 1998; 28(5): 876-83.
14. Stanley A, Osler T. Senescence and the healing rates of venous ulcers. *J Vasc Surg* 2001; 33(6): 1206-11.
15. Wlaschek M, Scharffetter-Kochanek K. Oxidative stress in chronic venous leg ulcers. *Wound Repair Regen* 2005; 13(5): 452-61.
16. Eming SA, Martin P, Tomic-Canic M. Wound repair and regeneration: mechanisms, signalling and translation. *Sci Transl Med* 2014; 6(265): 265sr6.
17. Pastar I, Stojadinovic O, Yin NC et al. Epithelialisation in wound healing: a comprehensive review. *Adv Skin Wound Care* 2014; 3(7): 445-64.
18. Dowsett C, et al. Taking wound assessment beyond the edge. *Wounds International* 2015. Vol 6(1). Available at http://www.woundsinternational.com/media/journals/_/1165/files/7wint_6-1_dowsett_etal.pdf [accessed 29 February 2016]
19. Langemo D, Anderson J, Hanson D, et al. Measuring wound length, width and area: which technique? *Adv Skin Wound Care* 2008; 21(1):42-7.
20. Leaper D, Schultz G, Carville K. et al. Extending the TIME concept: what have we learned in the past 10 years? *International Wound Journal* 2012; 9(Suppl 2): 1-19.
21. Schultz G, Sibbald RG, Falanga V et al. Wound Bed Preparation: a systematic approach to wound management. *Wound Repair Regen* 2003; 11(Suppl 1): S1-S28.
22. Dowsett C. Exudate management: a patient-centred approach. *Journal of Wound Care* 2008; 17(6): 249-52.
23. Cutting KF, White RJ. Criteria for identifying wound infection — revisited. *Ostomy Wound Management* 2005; 51(1): 28-34.
24. Moffat CJ (2005). *European Wound Management Association Position document: Identifying criteria for wound infection*. London: MEP Ltd 2008.
25. Harding KG. World Union of Wound Healing Societies. *Principles of Best Practice: Wound Infection in Clinical Practice. An International Consensus*. London MEP Ltd UK 2008. Available at: http://www.woundsinternational.com/media/issues/71/files/content_31.pdf [accessed 16 February, 2016].
26. Newton H, Cameron J. *Skin care in wound management*. Medical Communications Ltd, UK 2003.
27. Ongenaes KC, Phillips TJ, Park HY. Level of fibronectin mRNA is markedly increased in human chronic wounds. *Dermatologic Surgery: official publication for American Society for Dermatologic Surgery [et al]* 2000 May; 26(5): 447.
28. Lawton S, Langøen A. Assessing and managing vulnerable periwound skin. *World Wide Wounds* 2009. Available at: <http://www.worldwidewounds.com/2009/October/lawton-langoen/vulnerable-skin-2-utf8.html> [accessed 23.02.16]
29. Ousey K, Stephenson J, Barrett S et al. Wound care in five English NHS Trusts: results of a survey. *Wounds UK* 2013; 9(4): 20-8.
30. Gray M, Bohacek L, Weir D, Zdanuk J. Moisture vs pressure: making sense out of perineal wounds. *Journal of Wound Ostomy & Continence Nursing* 2007 March; 34(2): 134-42.
31. Cameron J. Exudate and the care of the periwound skin. *Nursing Standard* 2004; 19(7): 62-8.
32. Saap L, Fahim S, Arsenault E, et al. Contact sensitivity in patients with leg ulcerations: A North American study. *Arch Dermatol* 2004; 140(10): 1241-6.

Using the Triangle of Wound Assessment in the management of DFUs

Christian Münter, Specialist in General Medicine, Phlebology, Bramfelder Gemeinschaftspraxis, Hamburg, Germany

and **José Luis Lázaro Martínez**, Professor Titular de Universidad, Director Asistencial y Jefe Unidad Pie Diabético, Clínica Universitaria de Podología, Universidad Complutense de Madrid, Spain

Diabetic foot ulcers (DFUs) are complex, chronic wounds that have a major long-term impact on a patient's quality of life, morbidity and mortality^[1,2]. When compared to people without a history of DFU, those who develop a DFU are at increased risk of premature death, myocardial infarction and fatal stroke^[3]. The development and progression of a DFU, unlike other chronic wounds, can be complicated by diabetic changes, e.g. neuropathy and vascular disease. Along with the altered neutrophil function, diminished tissue perfusion and defective protein synthesis that often accompany diabetes, these present a unique and specific set of challenges for clinicians^[1].

To overcome these challenges, it is important for clinicians to take a holistic approach to the assessment of a DFU to identify intrinsic and extrinsic factors. This should take into consideration a full patient history, including medication, comorbidities and diabetic status, together with history of the wound, previous DFUs or amputations and any symptoms that suggest neuropathy. Integral to this approach is the assessment of not only the wound bed and wound edge but also the periwound skin. Frequent problems in the periwound skin area include maceration, excoriation, dry skin, hyperkeratosis, callus and eczema all of which, if overlooked, can result in delayed healing and heightened risk of infection. Prevalent periwound skin problems associated with DFUs include maceration, callus, hyperkeratosis and dry skin.

The Triangle of Wound Assessment is a simple and intuitive framework that builds on current concepts of wound bed preparation and TIME moving beyond the wound edge to provide a holistic assessment of the wound by including the periwound skin. The Triangle of Wound Assessment can easily be integrated with assessment and management of DFUs to help guide wound management.

UNDERSTANDING DIABETIC FOOT SYNDROME

Diabetes mellitus, as a systemic disease, impairs the body's metabolism, resulting in high glucose levels in tissues. In turn, raised blood sugar leads to further metabolic changes, all of which results in local hypoxia, ischaemia and impairment of nerves in the plantar tissue of the feet. The plantar tissue itself becomes altered and inelastic, and atrophy of the intrinsic musculature leads to claw toes and foot deformities^[8,9]. Moreover, the Achilles tendon and the plantar aponeurosis are damaged by hyperglycaemic metabolism, limiting mobility of the talocalcaneal joint (upper ankle joint). These deformities, combined with the metabolic and tissue changes caused by diabetes result in diabetic foot syndrome (DFS), which leaves a patient at high risk for the development of a DFU (Box 2).

Box 1: The impact of DFUs on health systems

- DFUs account for around 25% of all costs associated with diabetes care and account for 50% hospital stays among patients with diabetes^[4]
- The estimated cost of DFUs to health systems ranges from €7,700 for patients with healed wounds, to €8,600 for patients who died before healing, to €25,000 for patients who undergo major amputations^[5]
- In people with diabetes, a lower limb is amputated due to diabetes approximately every 20 seconds, an annual amputation rate in Europe of 0.5%– 0.8%^[6]
- About 85% of diabetes-related lower-extremity issues begin with foot ulceration^[6]
- The average annual cost for each patient with a DFU is calculated at €15,000^[7].

Box 2: DFUs in the population

- DFUs are likely to occur in around 25% of all patients with diabetes^[10,11]
- They are the most common reason for hospital admissions among patients with diabetes^[10,11]
- The incidence of DFUs (the probability of how many patients with diabetes mellitus will develop a DFU in a given time) is 2%, rising to 5%–7.5% if polyneuropathy is present^[12,13]
- The cumulative incidence of DFUs over 20 years for patients with type 1 diabetes is 10%^[12,13]
- The prevalence of DFUs (the percentage of patients with diabetes mellitus who actually have a DFU) is 3%^[14].

Box 3: Understanding DFU aetiologies

In diabetic wounds, clinicians should be aware of three key aetiologies that will influence assessment, treatment of the underlying condition and management of the DFU.

■ **Neuropathy**

Nearly all patients with DFS suffer from the loss of protective mechanisms due to neuropathy. Minor trauma, often associated with or resulting from unsuitable shoes, may start the destruction of the tissue^[15]. Neuropathy may be sensory (loss of sensitivity), autonomic (causes failure of sweat glands, leading to extremely dry skin) and/or motor (causes atrophy of foot muscles, which can deform bones of the foot).

■ **Ischaemia**

- Around 15% of patients with DFUs have concomitant ischaemia only (no neuropathy)^[16]. There are two types of ischaemia:
- Macro ischaemia — closely connected to risks factors such as hyperlipidemia and arterial hypertension which, together with obesity and diabetes, result in so-called metabolic syndrome. Typically several parts of the arterial system are involved, including the arteries in the pelvis and legs but, in 70% of diabetic cases, stenosis is found in the calves^[17]
 - Micro ischaemia — is not obstructive in the lower extremities^[18]. Results in the thickening of basal membranes of the vessels impairing microcirculation and delaying diffusion of oxygen in the tissue^[19].

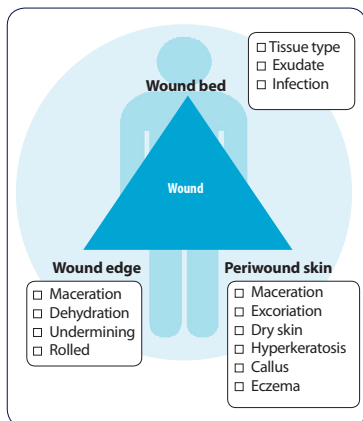
■ **Neuroischaemia**

When ischaemia presents with neuropathy, specifically the dysfunction of sympathetic nerve fibres, arteriovenous shunts widen, which consequently reduces oxygen levels in the skin^[19]. This is neuroischaemia, the most common chronic complication of diabetes.

Medial sclerosis (hardening of the arteries) leads to impairment of the arteries in the calves. Ischaemia is then found in the feet — not in the calves — making the normal symptom of peripheral artery disease (PAD) intermittent claudication (with pain in the calves) unreliable^[20]. Furthermore, the loss of sensitivity leads to artificially diminished levels of pain. In addition, it can increase the time it takes a patient to notice that there is skin damage.

The systemic aetiologies result in vulnerable tissue. When there are areas of pathologic pressure — due to deformities of the feet, inappropriate footwear, an injury or a combination of these causes — the likelihood of developing a DFU increases. Ulcers will be most often found in zones of pathologic pressure, usually over bony prominences (e.g. toes, sides of feet, heel, plantar surface).

Figure 1 | The Triangle of Wound Assessment. Adapted from^[23]



Optimal DFU management requires attention to three critical elements:

- Determining of aetiologic factors, followed by interventions to correct or ameliorate those factors when possible
- Assessing of systemic factors affecting wound repair, with measures to optimise the host’s ability to support the repair process
- Assessing of wound bed, wound edge and periwound skin status, as a basis for topical therapies to promote healing^[21].

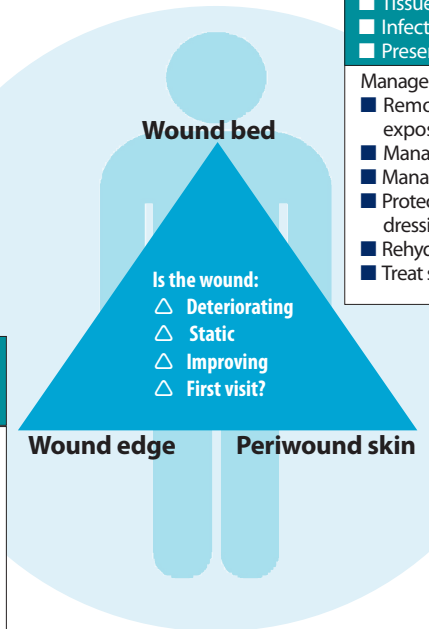
APPLYING THE TRIANGLE OF WOUND ASSESSMENT TO DFUs

The Triangle of Wound Assessment can be used to assess, manage and treat DFUs, helping to guide overall treatment. The simplicity of the three zones — wound bed, wound edge, and periwound skin — lends itself to being used by generalist practitioners to involve and engage patients and carers in the management of the wound (Figure 1).

Figure 2 | Using the Triangle of Wound Assessment in assessing and treating DFUs. Adapted from [23]

DFUs are complex, chronic wounds that have a major long-term impact on morbidity and mortality, and patient quality of life

Infection is a major threat of DFUs, much more so than in wounds of other aetiologies not subject to diabetic changes. As such, effective local wound care using the Triangle of Wound Assessment and infection control are paramount



Wound edge: special consideration

- Hyperaemic border
- Hyperkeratosis or calluses

Management plan

- Manage exudate (appropriate dressing)
- Discard ischaemia
- Rehydrate wound edge (e.g. barrier cream)
- Remove non-viable tissue (debridement)
- Protect granulation/epithelial tissue (e.g. non-adherent dressing)
- Reassess offloading efficacy

Wound bed: special consideration

- Tissue type can aid in determining aetiology
- Infection often presents itself with cellulitis and swelling
- Presence of bone, tendon or capsule

Management plan

- Remove non-viable tissue (debridement). Be aware of exposed tendon and capsule
- Manage exudate (appropriate dressing)
- Manage bacterial burden (e.g. antimicrobials)
- Protect granulation/epithelial tissue (e.g. non-adherent dressing)
- Rehydrate wound bed (e.g. hydrogel)
- Treat suspected osteomyelitis

Periwound skin: special consideration

- Callus recurrence

Management plan

- Manage exudate (appropriate dressing)
- Protect skin (e.g. barrier product/attraumatic dressings, avoid allergens)
- Rehydrate skin (e.g. emollients)
- Remove non-viable tissue (debridement)
- Prevent callus formation with offloading

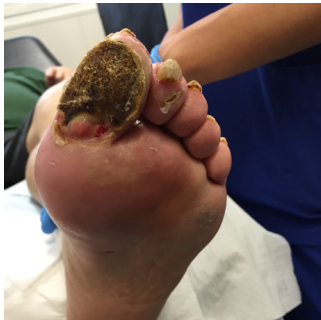In DFUs, the Triangle of Wound Assessment helps the clinician assess the wound to determine the aetiology, so that it can be concurrently managed (Box 3). The three interconnected zones of the Triangle of Wound Assessment provide a robust framework around which the distinct areas can be assessed thoroughly and monitored (Figure 2).

Wound bed: Baseline and serial measurements of the wound size, appearance and location will help establish appropriate interventions and aid monitoring of the response to treatment^[22]. It is important to measure and record accurately the tissue type of the DFU, which varies according to aetiology. The wound bed of a neuropathic DFU is often pink and granulating; that of an ischaemic ulcer is often pale and sloughy with poor granulation while neuroischaemic ulcers often have poor granulation. This does not preclude the presence of necrotic or sloughy tissue. Where wounds contain mixed tissue types, it is important to consider the predominant factors affecting healing and address these accordingly.

It is also important to measure and record the percentage of tissue visible in the wound bed along with details of exudate levels and type. With DFUs exudate levels may vary from dry to low and moderate to high. It is also vital to assess and record presence/levels of infection in the wound bed that could extend to the wound edge and periwound skin^[23]. Consistency of measurement is key: meaningful changes, e.g. alteration in tissue type, reduction in exudate, successful management of bioburden, should be tracked over a specified period of time (7-14 days)^[22].

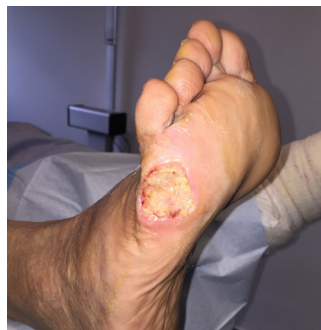Wound edge: To allow migration of epithelial cells across the wound bed during healing the wound edge needs to be moist and intact, and attached to and flush with the base of the wound. Assessment of the wound edge — identifying and recording presence of maceration, dehydration, undermining and rolled edges — provides information on the wound aetiology, how healing is progressing and whether the current treatment regimen is effective^[23].

Case 1: Dry necrotic tissue to the big toe



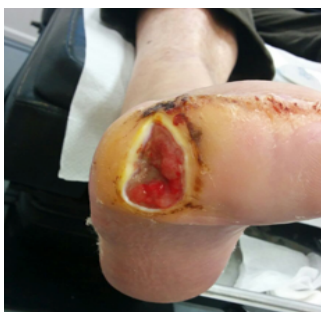Wound bed
Tissue type: Necrotic
Exudate levels: Low
Type of exudate: Cloudy
Infection: Malodour and local warmth

Case 2: Sloughy tissue over the metatarsal head of the 5th toe



Wound bed
Tissue type: Sloughy
Exudate levels: Medium
Type of exudate: Thin and watery
Infection: Erythema with increasing exudate and local warmth

Case 3: Hypergranulation



Wound bed
Tissue type: Granulating
Exudate levels: High
Type of exudate: Thick
Infection: Granulation tissue; friable and bleeding; oedema

Periwound skin: Issues affecting the periwound skin are common and can delay healing, cause discomfort and pain, lead to enlargement of the wound and result in poor quality of life for the patient.

High levels of exudate, which can occur in DFUs, present the biggest risk of damage to the periwound skin. It can slow down and prevent cell proliferation; interfere with growth factor availability and contains elevated levels of inflammatory mediators. Increased exposure to moisture reduces skin barrier function and increases the risk of skin breakdown and maceration.

Using the Triangle of Wound Assessment framework the periwound skin of a DFU should be assessed for signs of maceration, excoriation, dry skin, hyperkeratosis, callus and eczema. The extent of the problem should be recorded, e.g. distance from the wound edge. The aim is to protect the periwound skin to maintain healthy skin in the case of maceration, excoriation and dry skin.

FURTHER DFU EVALUATION

The Triangle of Wound Assessment provides an easy-to-use framework that can be fully integrated into a holistic patient assessment^[24], including indicators of aetiology; these should be carried out in addition to DFU-specific evaluations in order to confirm aetiology and cause of the wound:

- Neurological evaluation — to assess the presence and extent of neuropathy
- Vascular examination — to assess arterial perfusion; includes (1) initial palpation of pulses, (2) determination of ankle-brachial pressure index (ABPI), (3) supplemental toe blood pressure readings, pulse volume recordings, transcutaneous oxygen measurements and skin perfusion pressure measurements
- Evaluation of structural deformities — to identify abnormalities that may lead to wounds (e.g. hammer toes, bunions, Charcot deformities)
- Assessment of physical environment — to identify shoe pressure, repetitive plantar stress or repeated injury that could delay healing^[25].

These evaluations should be performed with the involvement of the multidisciplinary team, which may include podiatrist, specialist nurses, vascular surgeon, neurologist, general practitioner, dietician and other relevant healthcare providers as needed^[25].

USING THE TRIANGLE OF WOUND ASSESSMENT IN DFU PRACTICE

The Triangle of Wound Assessment has a role to play in the management of DFUs, based on the interpretation of some of the recommendations^[24].

Chronic wounds such as DFUs often present as shallow cavity wounds that may exude heavily. They produce increased levels of exudate due to a prolonged inflammatory phase of healing^[26].

WOUND BED MANAGEMENT

Wound bed evaluation is critical in the management of DFUs. Primarily, there are four types of wound tissue in a DFU; necrotic, sloughy, granulating and epithelialising.

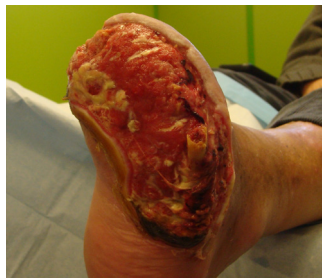There is also potential for two primary complications: the presence of bone and the presence of tendon or capsule within the wound bed. The Triangle of Wound Assessment framework can be used to record the presence of both, as well as levels of exudate and the possibility for infection.

Tissue type

Wound bed with necrotic tissue (Case 1)

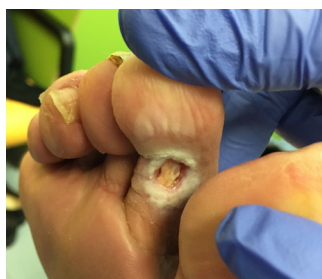Ischaemia is normally the main aetiology of a DFU, nevertheless an appropriate vascular evaluation is mandatory. The Triangle of Wound Assessment framework helps to record objectively the percentage of necrotic tissue. Pulses, palpation and ABPI are the basic

Case 4: A clean granulating wound bed however there is bone clearly visible



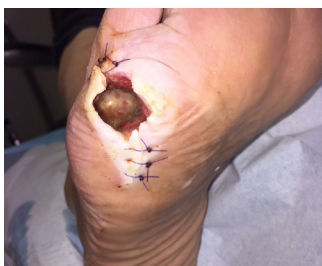Wound bed
Tissue type: Granulating
Exudate levels: High
Type of exudate: Thick
Infection: Granulation tissue. Bleeding with local warmth and malodour

Case 5: Tendon clearly visible in the base of the wound, note how the colour is similar to slough



Wound bed
Tissue type: Sloughy
Exudate levels: High
Type of exudate: Thin and watery
Infection: Increasing exudate and increasing pain

Case 6. Showing maceration of the periwound skin caused by high exudate levels



Wound bed
Tissue type: Sloughy 75%; granulating 25%
Exudate levels: High
Type of exudate: Cloudy
Infection: Increasing maceration with local warmth, malodour oedema

tests that should be performed to discount the presence of peripheral vascular disease. The aim is to remove the non-viable tissue, reduce the risk of infection, and protect and promote new tissue growth.

If necrosis is present in the wound bed of a patient with good vascular status (presence of both distal pulses and normal values from ABPI), necrosing soft tissue infections should be suspected. In this case other signs of infection could help in the diagnosis, these may include malodour, drainage of pus, erythema and pain, although this may be absent or abnormal in patients with an insensate foot.

Wound bed with sloughy tissue (Case 2)

The presence of sloughy tissue is a common challenge in DFUs. The main issue is distinguishing between slough and other tissues/structures with a similar colour or texture, e.g. tendon or capsule. This can be particularly challenging when DFUs are located beneath the metatarsal head or over the dorsum of the toes, where the tissue is very thin, and tendon and capsule could be easily exposed.

Wound bed with granulation tissue (Case 3)

Identifying the presence of granulation tissue can be complicated by the presence of hypergranulation (or over-granulation) tissue, which is common in patients with bone infections^[27]. Normal granulation is red with a slightly moist appearance but does not bleed easily, however over-granulation is frequently raised in a pediculate aspect and will bleed easily when touched. It is often bright cherry red in colour. The presence of hypergranulation frequently masks underlying infection, so it is important to record accurately the status of the wound.

Hypergranulation has a friable red, sometimes shiny and soft appearance that is above the level of the periwound skin. Research into the cause of hypergranulation is limited but there are a few common characteristics, including:

- Moist areas from exudates or bleeding
- Prolonged physical irritation or friction with continued repetitive minor trauma or pressure
- Excessive inflammation
- Bacterial bioburden or infection
- A new scenario of negative pressure suction with micro-deformation, particularly applicable to large pore foam dressings
- Low oxygen levels^[28].

Wound bed with bone exposed (Case 4)

The presence of exposed bone is a strong clinical indication of bone infection. If the bone is visible from the bottom of the ulcer or probe-to-bone is positive, then the osteomyelitis must be treated prior to any other interventions or treatment frameworks. A combination of X-rays, blood cultures and non-magnetic resonance (NMR) imaging could help in the diagnosis.

Wound bed with tendon or capsule exposed (Case 5)

In certain locations a DFU can expose a tendon or joint, in particular if they are beneath metatarsal heads, or on the toes. It is important to assess these wounds accurately as often the visible tissues (tendon, ligament or capsule) are mistaken for fibrin and consequently debrided, a course of action that can significantly increase the risk of infection, as well as have an impact on the patient should the tendon or ligament be damaged or severed, or the capsule removed. Asking the patient to move or wiggle his/her toes assists in confirmation of the tissue as tendon — movement of the digit will be seen in movement of the tendon.

Exudate (Case 6)

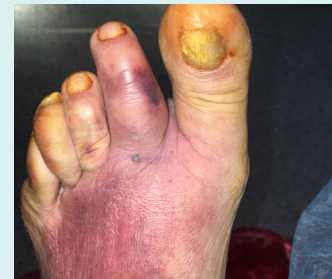The main cause of increased exudate is infection. Infections or high bioburden can increase exudate and lead to maceration or excoriation of both the wound edge and periwound skin.

Box 4: Signs and symptoms of infection

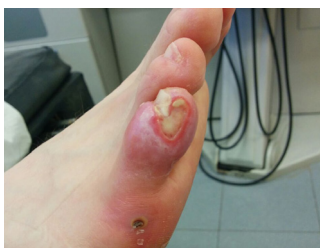Evidence of infection normally includes signs of inflammation:

- Redness or cellulitis (Case 7): Cellulitis is the main sign in the diagnosis and classification of infection in DFUs. When cellulitis spreads more than 2cm from the ulcer edges it would be classified as moderate or serious. The severity of cellulitis is particularly relevant to the diagnosis and prognosis of the infections in DFUs
- Vesicles and haematomas: Some deep infection can produce changes in skin colouration and integrity. Sometimes infection spreads through the subcutaneous tissue and produces vascular damage that causes haematomas over the skin. In these cases, an appropriate evaluation of the infection status of the wound is urgent in order to avoid serious complications
- Swelling is characteristic in soft tissue infections
- Tenderness or pain: Normally DFUs are not painful (particularly if the foot is insensate) but if the patient complains of pain or tenderness, infection should be suspected
- Probe-to-bone test is strongly associated with osteomyelitis. When bone could be touched through the ulcer it is highly probable that the bone is infected
- Friable or discoloured granulation tissue
- Malodour is a sign of infection and is striking in infections caused by anaerobic bacteria.

Case 7: Cellulitis and oedema of the forefoot, note the swollen, sausage like 2nd toe

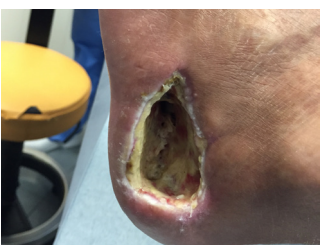

Case 8. Clearly demarcated hyperaemic border around the wound



Wound bed
Tissue type: Sloughy
Exudate levels: Low
Type of exudate: Thin and watery
Infection: Erythema with local warmth and delayed healing
Wound edge: Hyperaemic

Case 9. Showing a rolled edge in a long standing wound with slight maceration



Wound bed
Tissue type: Sloughy
Exudate levels: Medium
Type of exudate: Cloudy
Infection: Malodour and delayed healing and local warmth
Wound edge: Undermining, rolled edge and slight maceration

Neurological disorders could produce an increase in exudate, especially in patients with autonomic neuropathy, which affects vasomotor function and causes distal oedema. Distal oedema can result from cardiac or renal dysfunction. In diabetic patients, cardiovascular and renal complications are very frequent and could result in oedema and consequently high exudate in the wound.

High levels of exudate extend healing times, increase the risk of complications and increase the frequency of dressing change. Chronic wound exudate contains higher levels of inflammatory mediators and activated protein-digesting enzymes that can delay healing by breaking down the extracellular matrix of the wound bed and damaging the periwound skin^[26].

Effective management of exudate in DFU, using the Triangle of Wound Assessment can not only aid healing but also improve the patient experience and reduce the burden on healthcare resources^[26].

Infection

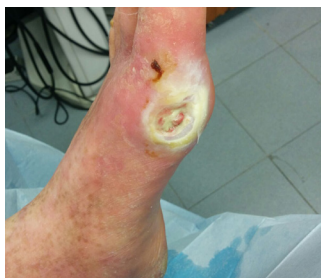Using the Triangle of Wound Assessment to record signs and symptoms of infection (Box 4) and exploration of the depth of the ulcer can help in the diagnosis. It must be remembered that some of the usual signs of infection may be absent in patients with diabetes. Infection is a major threat of DFUs, much more so than in wounds of other aetiologies not subject to diabetic changes. As such, effective local wound care using the Triangle of Wound Assessment and infection control are paramount.

WOUND EDGE MANAGEMENT

The condition of the wound edge in DFUs is important in wound assessments. The presence of a hyperaemic border (Case 8) could indicate the presence of ischaemia. Vascular evaluation should be performed in these patients in order to exclude the presence of peripheral vascular disease (PVD).

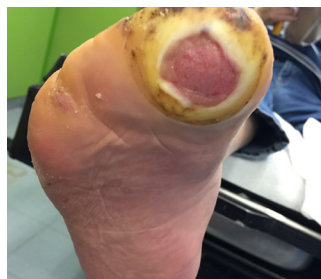Undermined edges frequently occur in DFUs especially when the ulcer is located beneath the metatarsal head. If a wound is undermined, the cavity should be examined for the presence of bone or exposed capsule. The position of the undermining should be detailed using the number positions on a clock face (Figure 3, page 8). The aim is to reduce the undermining using appropriate treatment that enables the edge to reattach (e.g. stimulate granulation).

Case 10. Macerated wound edges and periwound skin



Wound bed
Tissue type: Sloughy
Exudate levels: High
Type of exudate: Thick
Infection: Erythema and local warmth. Increasing exudate and malodour
Wound edge: Rolled edges
Periwound skin: Maceration and calluses
Cause: Bone infection
Treatment: Debridement of non-viable and infected tissues. Antimicrobials dressing and antibiotics

Case 11. Showing thick callous around the wound edge and periwound skin



Wound bed
Tissue type: Granulating
Exudate levels: High
Type of exudate: Thin and watery
Infection: Increasing exudate and local warmth
Wound edge: Rolled edges
Periwound skin: Maceration and calluses
Cause: Neuropathic oedema and high plantar pressure
Treatment: Offloading and compression; antimicrobial dressing. Debridement. Manage exudate with appropriate dressing

Rolled edges (Case 9) should be explored in order to exclude fistulous track or connections with deeper tissues. Osteomyelitis and joint infection could be the cause of this clinical presentation. However, rolled edges may simply be as a result of the chronicity of the wound. Early diagnosis is important in such cases to prevent poor healing outcomes. Clinicians should assess the amount of rolling (which may be associated with thickening) and aim is to return the wound edge to a condition that supports epithelial advancement (Figure 3, page 8).

PERIWOUND SKIN MANAGEMENT

Maceration (Case 10) is a consequence of increased volume of exudate. High levels of exudate alter the pH of the periwound skin and when it is poorly managed the subsequent change in acid mantle changes the bacterial balance/flora of the skin, reducing the balance needed for optimal healing. However, while maceration may result from poor exudate control related to inappropriate dressing selection, in the majority of DFU cases maceration is caused by infection or uncontrolled bioburden.

Hyperkeratosis and callus pattern distribution on the plantar surface could help in the evaluation of pressure distribution and its control by offloading. Hyperkeratosis or callus (Case 11) formation on the wound edge and periwound skin indicates poor or insufficient offloading and should be recorded and monitored using the Triangle of Wound Assessment framework. Pressure is the main cause of DFU and when calluses continue to form despite offloading, the offloading strategies should be revised. Patient understanding and compliance, absences of resources or poor selection and fitting of the offloading device are the main causes for offloading failing.

Xerosis and dry skin (Case 12) around the wound could indicate problems associated with PVD or neurological disorders. The primary assessment should be the exclusion of PVD by correct vascular assessment. Once this is ruled out other causes such as autonomic neuropathy may be considered. Irrespective of the cause maintaining the hydration of the skin in order to prevent skin cracks or fissures is very important as they can act as a portal for bacterial ingress and may be very painful. Cracks and fissures may also result in an extension of the wound margin.

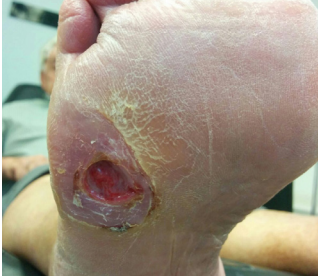Decisions about treatment type and suitability can only be reached once all three areas of the wound have been assessed.

CLASSIFYING DFUs

Taking into account the results of the Triangle of Wound Assessment, as well as the further evaluations required to ensure holistic assessment and treatment of DFUs, the wound should then be classified according to a validated clinical tool^[29].

Box 5: University of Texas Diabetic Wound Classification System				
Stage	Grade			
	0	I	II	III
A (no infection or ischaemia)	Pre- or post-ulcerative lesion completely epithelialised	Superficial wound not involving tendon, capsule or bone	Wound penetrating to tendon or capsule	Wound penetrating to bone or joint
B	Infection	Infection	Infection	Infection
C	Ischaemia	Ischaemia	Ischaemia	Ischaemia
D	Infection and ischaemia	Infection and ischaemia	Infection and ischaemia	Infection and ischaemia

Case 12. Showing dry skin probably related to autonomic neuropathy



Wound bed

- Tissue type:** Granulating
- Exudate levels:** Low
- Type of exudate:** Thin and watery
- Infection:** No signs
- Wound edge:** Undermining
- Periwound skin:** Hyperkeratosis and dry skin
- Cause:** Neuropathy and high plantar pressure
- Treatment:** Offloading. Emollients. Protect granulation tissue

The SINBAD (site, ischaemia, neuropathy, bacterial infection and depth) framework uses a scoring system that helps predict outcomes, and is a simplified version of a previous classification system; however, although it is comprehensive and attempts to be useful across geographies, SINBAD is not well established in existing literature^[6]. The PEDIS is similarly not well established, as it was developed quite recently (2012) and there are few categories for classification, but it is user-friendly and can be used by clinicians who do not have as much experience of managing DFUs^[6].

There are two well established classifications. The first is the Wagner scale, which assesses ulcer depth along with presence of gangrene and loss of perfusion over six grades (0 – 5); however, it does not fully take into account infection and ischaemia^[6]. The University of Texas (Armstrong) scale may be the most well received, as it accounts for all aspects of assessment and cross-references them against one another, to devise a two-part score that includes grade and stage^[6]. Thus it lets the clinician gain a complete picture of the individual wound (Box 5).

EXAMINATION OF THE ULCER

A physical examination should determine:

- Is the wound predominantly neuropathic, ischaemic or neuroischaemic?
- If ischaemic, is there critical limb ischaemia?
- Are there any musculoskeletal deformities?
- What is the size/depth/location of the wound?
- What is the colour/status of the wound bed?
 - Black (necrosis)
 - Yellow, red, pink
- Is there any exposed bone?
- Is there any necrosis or gangrene?
- Is the wound infected? If so, are there systemic signs and symptoms of infection such as fevers, chills, rigors, metabolic instability and confusion?
- Is there any malodour?
- Is there local pain?
- Is there any exudate? What is the level of production (high, moderate, low, none), colour and consistency of exudate, and is it purulent?
- What is the status of the wound edge (callus, maceration, erythema, oedema, undermining)?
- What is the status of the periwound skin (maceration, excoriation, dry skin, hyperkeratosis, callus, eczema)?

Using the Triangle of Wound Assessment to record size, depth, appearance and location along with detailed information about the tissue type of the wound bed, and the status of the wound edge and the periwound skin, will help to establish a baseline for care, develop a plan for treatment and evaluate any response to treatment.

DEVISING A TREATMENT PLAN

Together with the classification of a DFU, the Triangle of Wound Assessment enables the accurate and timely wound assessment of each individual and forms the basis of an appropriate and holistic management plan that takes into consideration medical condition, cause, duration and status of the wound and any factors that may prevent healing, e.g. comorbidities, medications, infection, age etc. The main goal is often wound healing, however this may not be appropriate in all patients in who the main objective may be to provide comfort and to control exudate and odour.

SUMMARY

DFS is complex and costly to patients and health systems alike (Boxes 1 and 2). Because DFS incorporates endocrine, histologic, neurologic, ischaemic and orthopaedic factors, it

is important that DFU assessment — starting with the Triangle of Wound Assessment framework — be holistic and multidisciplinary. The focus should not only be on evaluating and managing the wound, but also on the periwound skin, and on diagnosing and treating the underlying systemic aetiology.

Accurate wound assessment based of the Triangle of Wound Assessment in DFU could be helpful for developing a plan of care (see Figure 1, page 20). Determination of the tissue type is critical before debridement, as is understanding of the cause of each type of tissue. It is important to know when the patient has ischaemia or infection, especially when the infection is deep and involves the bone, capsule or joint.

Sharp debridement should only be performed when the arterial supply is not significantly impaired and when infection is ruled out. Sharp debridement is currently the best way to remove non-viable tissue, as it is rapid and easily performed by a skilled clinician.

The presence of exudate is often associated with foot infection, autonomic neuropathy or after a revascularisation. Discounting the presence of infection is critical before managing the increased levels of exudate.

Without doubt infection is the main complication in DFU. Some infections threaten the limb and sometimes even the life of the patient. Infection is a common complication in DFUs, therefore an accurate diagnosis is mandatory in every ulcer.

Assessment of the wound edges could provide information about the appropriate management of a DFU. Presence of callus or hyperkeratosis is always associated with high pressure on the ulcer. Aggressive, effective and efficacious offloading is mandatory in DFUs, being part of a standard care regimen. Xerosis and hyperkeratosis are also common findings. Hydration of the periwound skin and callus removal should be done frequently.

Maceration of the periwound is normally a consequence of poor control of exudate. In the majority of the cases if the underlying cause is correctly managed, maceration improves, but the choice of an appropriate dressing is also critical to avoid ulcer extension and spread of damages.

These wounds may then be classified according to an accepted scoring system, to help guide monitoring and management. The chances that these wounds will heal spontaneously are limited because the underlying systemic disease — diabetes mellitus — impairs the process of normal wound healing. However, by adopting a holistic approach to wound healing, with appropriate referrals and multidisciplinary involvement, DFUs can be healed and limbs saved^[30].

The Triangle of Wound Assessment together with specific DFU assessment methods enable HCPs to better devise, implement and evaluate a treatment plan for patients.

REFERENCES

1. National Institute for Health and Clinical Excellence. *Diabetic foot problems: inpatient management of diabetic foot problems. Clinical guideline 119*. London: NICE, 2011. Available at: <http://publications.nice.org.uk/diabetic-foot-problems-cg119>. (accessed March 2013 2).
2. Abetz L, Sutton M, Brady L, et al. The diabetic foot ulcer scale: a quality of life instrument for use in clinical trials. *Practical Diabetes International* 2002; Jul 1;19(6): 167-75
3. Brownrigg JR, Davey J, Holt et al. The association of ulceration of the foot with cardiovascular and all-cause mortality in patients with diabetes: a meta-analysis. *Diabetologia* 2012; 55(11): 2906-12.
4. Liebl A, Neiss A, Spannheimer A, et al. Kosten des Type 2 Diabetes in Deutschland. *Dtsch Med Wochenschr* 2001; 126(20): 585-9.
5. Prompers L, Huijberts M, Schaper N, et al. Resource utilisation and costs associated with the treatment of diabetic foot ulcers. *Diabetologia* 2008; 51(10): 1826-34.
6. *International Best Practice Guidelines: Wound Management in Diabetic Foot Ulcers*. Wounds International, London 2013. Available at: www.woundsinternational.com
7. Girod I, Valensi P, Laforêt C, et al. An economic evaluation of the costs of diabetic foot ulcers. *Diabet Metab* 2003; 29(3): 269-72.
8. Jorreskog G. Why critical limb ischemia criteria are not applicable to diabetic foot and what the consequences are. *Sc and J Surg* 2012; 101 (2): 114-8.
9. Jude EB, Oyibo SO, Chalmers N, Boulton AJ. Peripheral arterial disease in diabetic and non-diabetic patients: A comparison of severity and outcome. *Diabetes Care* 2001; 24(8): 1433-7.
10. Mayfield JA, Reiber GE, Sanders LJ, et al; American Diabetes Association. Preventive foot care in people with diabetes. *Diabetes Care* 2003; 26 Suppl 1: S78-9.
11. Singh N, Armstrong DA, Lipsky BA. Preventing foot ulcers in patients with diabetes. *JAMA* 2005; 293(2): 217-28.
12. Abbott CA, Carrington AL, Ashe H, et al; North-West Diabetes Foot Care Study. The North-West Diabetes Foot Care Study: incidence of, and risk factors for, new diabetic foot ulceration in a community-based patient cohort. *Diabet Med* 2002; 19(5): 377-84.
13. Moss SE, Klein R, Klein BE. The 14-year incidence of lower-extremity amputations in a diabetic population. The Wisconsin Epidemiologic Study of Diabetic Retinopathy. *Diabetes Care* 1999; 22(6): 951-9.
14. Sämman A, Tajiyeva O, Müller N, et al. Prevalence of the diabetic foot syndrome at the primary care level in Germany: a cross-sectional study. *Diabet Med* 2008; 25(5): 557-63.
15. Trengrove NJ, Bielefeldt-Ohmann H, Stacey MC. Mitogenic activity and cytokine levels in non-healing and healing chronic leg ulcers. *Wound Repair Regen* 2000; 8(1): 13-25.
16. Armstrong DG, Cohen K, Courric S, et al. Diabetic foot ulcers and vascular insufficiency: Our population has changed, but our methods have not. *J Diabetes Sci Technol* 2011; 5(6): 1591-5.
17. Andreisek G, Pfammatter T, Goepfert K, Nanz D, Hervo P, Koppensteiner R, Weishaupt D. Peripheral Arteries in Diabetic Patients: Standard Bolus-Chase and Time-resolved MR Angiography 1. *Radiology* 2007 Feb; 242(2): 610-20.
18. Mast BA, Schultz GS. Interactions of cytokines, growth factors and proteases in acute and chronic wounds. *Wound Repair Regen* 1996; 4(4): 411-20.
19. ICW (Initiative chronische Wunde) 2016
20. Macfarlane RM, Jeffcoate WJ. Factors contributing to the presentation of diabetic foot ulcers. *Diabet Med* 1997; 14(10): 867-70.
21. Krapfl L, Pierce B. General principles of wound management. In: Doughty D and McNichol L (eds). *WOCN Core Curriculum: Wound Management*. Philadelphia, USA. Lippincott Williams & Wilkins 2015.
22. Baranoski S, Ayello E A, Langemo D K. Wound assessment. In: Baranoski S, Ayello EA (eds). *Wound care essentials: practice principles*. Philadelphia: Lippincott Williams and Wilkins, 2012: 101-25.
23. Dowsett C, Protz K, Drouard M, Harding KG. *Triangle of Wound Assessment Made Easy*. Wounds International May 2015. Available at: <http://www.woundsinternational.com/made-easys/view/triangle-wound-assessment> (accessed 16.03.16)
24. Mills JL Sr, Conte MS, Armstrong DG; Society for Vascular Surgery Lower Extremity Guidelines Committee. The Society for Vascular Surgery Lower Extremity Threatened Limb Classification System: risk stratification based on wound, ischemia, and foot infection (WIFI). *J Vasc Surg* 2014; 59(1): 220-34.
25. Frykberg RG, Banks J. Challenges in the treatment of chronic wounds. *Adv Wound Care (New Rochelle)*. 2015; 4(9): 560-82.
26. Chadwick P, McCardle J. Exudate management using gelling fibre dressing. *The Diabetic Foot Journal* 2015; 8(1): 43-48
27. Lipsky BA, Berendt AR, Cornia PB et al. Infectious Diseases Society of America clinical practice guideline for the diagnosis and treatment of diabetic foot infections. *Clin Infect Dis* 2012; 54:e132-e173.
28. Widgerow AD, Leak K. Hypergranulation tissue: evolution, control and potential elimination. *Wound Healing Southern Africa*. 2010 Oct 29; 3(2):7-9. Available at: www.woundhealingsa.co.za/index.php/WHSA/article/viewFile/87/127. (accessed 8 April, 2016)
29. Lavery LA, Armstrong DG, Harkless LB. Classification of diabetic foot wounds. *J Foot Ankle Surg* 1996; 35: 528-31.
30. Armstrong DG, Lavery LA, Harkless LB. Validation of a diabetic wound classification system. The contribution of depth, infection, and ischemia to risk of amputation. *Diabetes Care* 1998; 21(5): 855-9.

NOTES

NOTES



A Wounds International publication
www.woundsinternational.com